JOURNAL OF THE AMERICAN COLLEGE OF CARDIOLOGY
VOL. 71, NO. 10, 2018

PUBLISHED BY ELSEVIER

Spectrum of Restrictive and Infiltrative Cardiomyopathies

Part 2 of a 2-Part Series

Naveen L. Pereira, MD,[a] Martha Grogan, MD,[a] G. William Dec, MD[b]

ABSTRACT

Restrictive cardiomyopathies are the least common form of heart muscle disease. They are characterized as infiltrative and noninfiltrative, storage diseases, and endomyocardial disorders. Genetic diseases commonly present during childhood or adolescence. However, a growing percentage of elderly patients with heart failure with preserved ejection fraction are being recognized as having forms of restrictive cardiomyopathy, particularly cardiac amyloidosis. Noninvasive evaluation has replaced endomyocardial biopsy in the diagnostic evaluation of most suspected etiologies. The detection of infiltrative cardiomyopathies, particularly primary and secondary forms of iron overload, as well as inflammatory diseases such as sarcoidosis has slowly led to improved outcomes via disease-specific therapies. (J Am Coll Cardiol 2018;71:1149–66) © 2018 by the American College of Cardiology Foundation.

Restrictive and infiltrative cardiomyopathies are the least frequently encountered form of primary heart muscle disease in adults within the developed world (1,2). The first part of this review focused on idiopathic restrictive cardiomyopathy (RCM), storage disorders such as Fabry disease, and cardiac amyloidosis. This second part discusses endomyocardial fibrosis; infiltrative cardiomyopathies, particularly sarcoidosis; primary and secondary forms of iron overload cardiomyopathy; and radiation-induced forms of disease.

ENDOMYOCARDIAL DISEASES

Endomyocardial diseases are another rare cause of RCM; the most common is endomyocardial fibrosis (EMF). Several conditions share the pathologic phenotype, but a variety of distinct causes have been identified. Other diseases are endocardial fibroelastosis (EFE), hypereosinophilic syndromes (HES), and carcinoid heart disease (3).

ENDOMYOCARDIAL FIBROSIS

EMF was initially described in Uganda and is the most common cause of RCM, affecting >12 million people worldwide (4). EMF is commonly seen in equatorial countries such as Uganda, Nigeria, and Brazil; it accounts for approximate 20% of heart failure cases and 15% of cardiac deaths in equatorial Africa (4–6). Although rarely observed in North America, other conditions such as hypereosinophilic syndrome may mimic this disorder. EMF typically affects impoverished young adults with a bimodal distribution peaking at 10 and 30 years of age (5). Malnutrition, parasitic infections, genetic factors, and cluster ethnicity have all been proposed as etiological factors. Immunological investigation has demonstrated the presence of autoantibodies (immunoglobulin G and M) directed against myocardial proteins (7,8). A popular diet-related hypothesis proposes a pathogenic role for the cassava plant. This foodstuff contains a toxic cyanogenic glycoside, linamarin, that may produce tissue hypoxia and lipid peroxidation, which are proposed as mediators of myocardial damage when not properly processed (4). Malnutrition may also contribute by increasing susceptibility to parasitic and helminthic infections, which, in turn, may trigger a detrimental eosinophilic response, and poor protein intake may attenuate the detoxification

Listen to this manuscript's audio summary by *JACC* Editor-in-Chief Dr. Valentin Fuster.

From the [a]Department of Cardiovascular Diseases, Mayo Clinic, Rochester, Minnesota; and the [b]Cardiology Division, Massachusetts General Hospital, Boston, Massachusetts. Dr. Pereira is funded in part by the National Institute on Aging grant R21AG53512. Dr. Grogan has received consulting fees from Alnylam, Pfizer, and Prothena; and has received research support from Alnylam and Pfizer. Dr. Dec has reported that he has no relationships relevant to the contents of this paper to disclose. Robert James Siegel, MD, served as Guest Editor for this paper.

Manuscript received October 5, 2017; revised manuscript received January 10, 2018, accepted January 10, 2018.

ISSN 0735-1097/$36.00
https://doi.org/10.1016/j.jacc.2018.01.017

JACC VOL. 71, NO. 10, 2018
MARCH 13, 2018:1149–66

ABBREVIATIONS AND ACRONYMS

CMR = cardiac magnetic resonance imaging

EFE = endocardial fibroelastosis

EMF = endomyocardial fibrosis

HES = hypereosinophilic syndromes

HH = hereditary hemochromatosis

IOC = iron overload cardiomyopathy

PET = positron emission tomography

RCM = restrictive cardiomyopathy

of dietary cassava-derived cyanide (9,10). It is likely that a combination of dietary, environmental, and infectious factors combine in a susceptible individual to produce an inflammatory process leading to progressive endomyocardial damage and scarring (11).

The natural history of EMF is well documented and includes an active phase with inflammation and eosinophilia that progresses to a chronic phase leading to restrictive heart disease (4). In the chronic phase, biventricular involvement is the most common presentation (>50% of cases), followed by isolated right-sided heart involvement (5). When right ventricular restriction predominates, chronic venous hypertension often results in facial edema and exophthalmos, marked jugular venous distention, hepatomegaly, and ascites. Ascites is often seen out of proportion to peripheral edema. The presence of ascites with lymphocytic exudates and peritoneal fibrosis suggests that EMF is a systemic syndrome with periods of active peritoneal inflammation (12,13). Atrial fibrillation occurs in >30% of patients and embolic complications are common (2,14,15).

Echocardiography typically demonstrates small ventricles, normal wall thickness, severely dilated atria, and valvular dysfunction due to global fibrosis (16,17). In advanced right-sided EMF, the cardiac apex is severely retracted and the trabecular chamber is almost obliterated. Severe tricuspid regurgitation is also present. In biventricular EMF, progressive entrapment of the posterior mitral leaflet results in severe regurgitation without ventricular remodeling (16). Marked restrictive inflow pattern is noted on Doppler echocardiography. Cardiac magnetic resonance imaging (CMR), when available, can provide additional information regarding the extent of chamber distortion and LV cavitary thrombus burden. Late gadolinium enhancement correlates well with extent of fibrosis (18).

Medical management consists of sodium and fluid restriction, diuretics, and aspirin or anticoagulation in view of the potential for intracardiac thrombi. Long-term outcome for medical treatment in advanced stages is very poor, with 75% mortality reported at 2 years (2,4). Where surgical expertise exists, EMF may be successfully treated with surgical endocardectomy and valve repair or replacement (19,20). Survival rates as high as 70% at 10 years have been reported (19).

ENDOCARDIAL FIBROELASTOSIS

EFE is characterized by diffuse thickening of the LV endocardium secondary to proliferation of fibrous and elastic tissue. Two forms have been described: a dilated form (DCM phenotype), in which the LV is enlarged, and a "contracted" form (RCM phenotype), in which the LV cavity is small (21). A familial pattern is seen in the majority, with presentation commonly during infancy. The primary form of EFE invariably affects the LV with significant involvement of the mitral and aortic valves. Isolated right ventricular involvement may rarely occur. The "contracted" form produces restrictive hemodynamics and a clinical picture of left-sided obstructive disease, particularly if the mitral valve is involved. EFE is extremely rare and may respond to surgery.

HYPEREOSINOPHILC SYNDROMES

Hypereosinophilia is defined as an absolute peripheral blood eosinophil count that is >1,500 cells/l and persists for longer than a month or pathological evidence of hypereosinophilic tissue invasion. HES affecting the heart (formerly known as Loeffler's endocarditis), although very rare, can cause substantial morbidity and mortality through the release of highly active biological substances that damage the endothelium and myocardium, which leads to eosinophilic myocarditis (22). Most patients are diagnosed between the ages of 20 and 50 years (23,24). Mechanisms of eosinophilia are quite variable and include helminthic and parasitic infections, malignancies, eosinophilic leukemia, allergic drug reactions, or idiopathic causes (22,24). Certain variants of HES, particularly those associated with aberrations in the gene for platelet-derived growth factor alpha and beta, occur almost exclusively in males, whereas others (e.g., the lymphocytic variant of HES driven by interlukin-5 expression and HES of unknown etiology) are equally distributed between the sexes (25). It should be noted that eosinophilic myocarditis can also occur independent of HES. Other etiologies include hypersensitivity and eosinophilic granulomatosis with polyangiitis.

Eosinophilic heart disease has been categorized into 3 stages: an acute necrotic phase; an intermediate phase with thrombus formation; and a fibrotic stage characterized by impaired cardiac function, heart failure due to RCM, and/or fibrotic deformation of chordal structures leading to mitral and tricuspid

FIGURE 1 Echocardiographic Findings in Eosinophilic Heart Disease

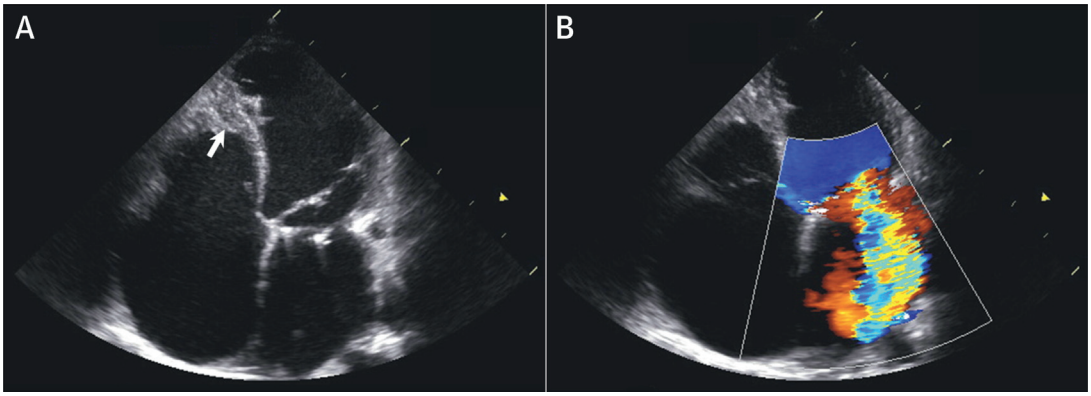

(A) Apical 4-chamber image demonstrating thrombosis/fibrosis obliterating the right ventricular apex **(arrow)**, which is typical for this condition. Severe biatrial enlargement with normal left ventricular chamber size is also noted. **(B)** Apical 4-chamber color Doppler image demonstrating severe mitral valve regurgitation in the setting of prior mitral valve repair. Images courtesy of Dr. S. Allen Luis, Mayo Clinic.

regurgitation (22,24). The acute necrotic stage is characterized by endothelial damage, myocardial infiltration with eosinophils and lymphocytes, eosinophil degranulation, and pronounced myocardial necrosis. Serum troponin levels are generally elevated. Echocardiography is typically normal at this stage of disease (26,27). CMR can reliably detect all stages of disease (27,28). Endomyocardial biopsy will provide definitive evidence of eosinophil-associated myocardial involvement, but is typically reserved for patients in whom there is uncertainty about the cause of the cardiac disease (22,24). The second stage of heart disease includes thrombus formation in areas of damaged endothelium. Tissue factor is expressed by eosinophils and may play a direct role in thrombus propagation (29). Embolic complications leading to stroke and/or limb ischemia are not uncommon. Cardiac imaging studies reveal extensive mural thrombus with partial ventricular obliteration by clot (28).

The fibrotic stage results in RCM due to extensive endomyocardial fibrosis. Hypereosinophilic EMF or late stage Loeffler's endomyocardial disease occurs in temperate zones but has all of the clinical and pathological features of tropical EMF (2). Fibrotic remodeling of valvular structures leading to impaired valvular mobility and fusion of valves directly to the endocardial surface are the major pathological findings (26). Echocardiography (**Figure 1**) and CMR show characteristic findings of intracardiac thrombi and/or endocardial fibrosis (26-28).

Treatment can be effective in the early stages of disease. Corticosteroids alone or in combination with cytolytic therapies (hydroxyurea, inferon alpha) have been shown to improve the acute necrotic stage of disease with substantial increases in left ventricular ejection fraction (LVEF) and decreased symptoms (30,31). The role for systemic anticoagulation in the management of patients with documented intracardiac thrombi remains controversial. Current recommendations suggest that anticoagulation should be instituted for patients who have sustained a prior embolic event. The presence of a documented thrombus may not be sufficient to justify anticoagulation, as treatment failures are not uncommon. The fibrotic stage may occasionally require surgical therapy, which may include resection of endocardial scar as well as subchordal repair and/or valve repair or replacement (31,32). The need for cardiac surgery has declined during the last decade due to aggressive management strategies aimed at preventing unregulated eosinophil proliferation. Surgical replacement of the mitral or aortic valves must be accompanied by pharmacological measures designed to control ongoing eosinophilia (31). Bioprosthetic valves are preferable to mechanical valves due to the thrombotic tendency of HES patients. Prosthetic valve obstruction occurs when marked hypereosinophilia is not adequately controlled on pharmacological therapy (31).

IRON OVERLOAD CARDIOMYOPATHY

Iron overload cardiomyopathy (IOC), regardless of its origin, is characterized in early stages by a RCM with prominent early diastolic dysfunction that inevitably

JACC VOL. 71, NO. 10, 2018
MARCH 13, 2018:1149–66

TABLE 1 Conditions Associated With Iron Overload Cardiomyopathy

Primary Hemochromatosis	
Classical (Type 1)	
Mutation:	*HFE* gene (C282Y or H63D)
Inheritance:	Autosomal recessive
Nonclassical (Type 2)	
Mutation:	Subtype A-hemojuvelin [iron-regulatory protein] (*HJV* gene)
	Subtype B- hepcidin (*HAMP* gene)
Inheritance:	Autosomal recessive
Nonclassical (Type 3)	
Mutation:	Transferrin receptor (*TfR2* gene)
Inheritance:	Autosomal recessive
Nonclassical (Type 4)	
Mutation:	Ferroportin [iron exporter protein] (*SLC40A1*)
Inheritance:	Autosomal dominant
Secondary Iron-Overload	
Acquired anemias	
Hemoglobinopathies: Alpha and beta thalassemia and sickle cell anemia, sideroblastic anemia	
Acquired anemias	
Myelodysplastic syndromes	
Myelofibrosis	
Aplastic anemia	
End-stage renal disease receiving intravenous iron supplementation	
Other conditions	
Friedreich's ataxia (mitochondrial iron-overload)	
Congenital atransferrinemia	

Data from Murphy et al. (33).

progresses to an end-stage dilated cardiomyopathy (33-35). Excess iron accumulation usually occurs due to increased gastrointestinal (GI) iron absorption (e.g., hemochromatosis) or high parenteral iron administration, generally due to frequent red blood cell transfusions (**Table 1**) (33) especially in hereditary anemias such as thalassemia major and sickle cell disease. In iron overload, iron in the circulation typically exceeds serum transferrin iron-binding capacity, leading to the appearance of nontransferritin bound iron, an expansion of the labile intracellular iron pool, and formation of highly reactive oxygen free radicals causing peroxidation of membrane lipids and oxidative damage to cellular proteins (36). Iron impairs mitochondrial function in combination with free oxygen radicals by peroxidation of polyunsaturated fatty acids within membrane phospholipids and mitochondrial deoxyribonucleic acid damage (37). Iron disrupts lysosomal membranes resulting in cell death. Iron enters cardiac myocytes in the ferrous (Fe^{2+}) form through voltage gated L-type calcium channels and is converted to ferric iron (Fe^{3+}), which interferes with normal excitation-contraction coupling in myocytes (33). In experimental models, Fe^{2+} results in a net increase in calcium influx, which may contribute to the impaired diastolic function that is observed during the early stage of iron overload (38-40). Pathological iron deposition initially begins in the epicardium, then extends to the myocardium and finally to the endocardium, which partially explains preservation of systolic function until late in the disease (41).

GENETICS. Hereditary hemochromatosis (HH) is an autosomal disorder in which mutations of specific genes involved in iron metabolism cause iron overload in the body due to increased GI absorption (34). There is a low rate of disease penetrance particularly among female genetic variant carriers. The association of IOC with HH has been well described for many years (42). However, IOC occurs far more frequently in secondary forms of iron overload than HH. It has been classified into 4 subtypes. Type 1 primary hemochromatosis (classic HH) is an autosomal recessive disorder linked to mutations in the *HFE* gene that encodes a protein directly involved in controlling GI absorption of iron. Mutations in the *HFE* gene involve either a single base pair change resulting in tyrosine for cysteine substitution at position 282 (C282Y) or a substitution of aspartate for histidine at position 63 (H63D) (33,36). Type 2 HH is associated with mutations of the *HFE2* gene that encodes for homojuvelin, a protein that interacts with hepcidin (subtype 1A) or in the *HAMP* gene that encodes for hepcidin, a key regulator of circulating iron (subtype 2B). Type 3 HH results are mutations in the *TfR2* gene that encodes for transferrin receptor 2. Finally, type 4 HH is caused by mutations in the *SLC40A1* gene that encodes for ferroportin, a protein that is involved in iron efflux (35).

CLINICAL FEATURES. Types 1 and 4 hemochromatosis generally manifest in adulthood, usually during the fourth or fifth decades of life, whereas type 2 (also called juvenile hemochromatosis) typically presents by the second decade with a more severe phenotype accompanied, in addition to cardiomyopathy, by hypogonadotropic hypogonadism, arthropathy, and liver fibrosis or cirrhosis. The onset of type 3 hemochromatosis is usually intermediate between types 1 and 2 and occurs before age 30 years. The typical clinical hemochromatosis triad of cirrhosis, skin bronzing, and diabetes mellitus is extremely variable and is often absent (33).

Secondary iron overload occurs primarily in patients with hereditary anemias, particularly alpha-thalassemia, beta-thalassemia and sickle cell anemia (33,34). A reduction in childhood mortality from

infection and malnutrition coupled with an increased use of blood transfusions has led to a growing incidence of iron overload in patients with these disorders (35). In older adults, IOC often results from treatment of myelodysplastic syndrome or end-stage renal failure (secondary to intravenous iron supplementation).

Cardiovascular disease is a major cause of death in iron overload conditions worldwide, typically occurring in the second and third decades of life (42). IOC is the most important determinant of survival in European, North American, and Chinese patients with thalassemia major (42,43). Initial clinical presentation is often exertional dyspnea due to LV diastolic dysfunction secondary to restrictive physiology (44). Sudden death risk is also increased in this population (45). In the early stages of disease, restrictive LV filling by transmitral and pulmonary vein diastolic Doppler indexes has been reported in 8% to 50% of patients (40,44,46). Not surprisingly, diastolic dysfunction was more pronounced in patients with advanced age. First-degree atrioventricular (AV) block and supraventricular arrhythmias, including paroxysmal atrial fibrillation, are not uncommon, but ventricular arrhythmias are infrequent. Elevation in circulating natriuretic peptides has been reported to identify early disease (47,48). In a minority of cases (<10%), restrictive LV dysfunction leads with advancing age to the development of pulmonary hypertension, right ventricular dilation, and right-sided heart failure without evidence LV remodeling and continued preservation of LVEF, the so-called restrictive phenotype (40,49).

DIAGNOSTIC EVALUATION. Plasma transferrin saturation >55% and serum ferritin >200 or 300 ng/ml (for women and men, respectively) have been proposed as indicators of iron overload (50). Transferrin saturation alone fails to detect a substantial portion of patients who are homozygous for HFE mutations (51). Clinicians should recognize that elevated serum ferritin levels may result from other causes besides iron overload, including inflammation from active infection or cancer, and correlates poorly with severity of cardiac disease (33). Genetic screening for the C282Y and H63D HFE mutations for type 1 hemochromatosis are now widely available and provide the basis for family counseling. Similarly, hemoglobin electrophoresis for the detection of congenital hemoglobinopathies is now routine. Plasma B-type natriuretic peptide provides a valid prognostic marker of outcome in IOC and should be measured in all suspected cases (52,53).

Echocardiography is the main imaging modality used to screen patients with suspected IOC and for regular clinical follow-up. Unlike most infiltrative cardiomyopathies, LV wall thickness is not increased in IOC. Impaired diastolic LV function featuring pseudonormalization and restrictive filling patterns by Doppler, with or without left atrial enlargement, constitutes early findings (40,44). As the disease progresses, left and right ventricular dilation and reduction in LVEF (the dilated phenotype), or alternatively, restrictive LV filling with right ventricular dilation, increased pulmonary artery pressures, and preserved LVEF (the restrictive phenotype) will occur (35). However, IOC occurs far more frequently in secondary forms of iron overload.

The time course for progression from diastolic dysfunction to RCM and then dilated cardiomyopathy is unknown and is probably highly variable. Further, the frequency with which IOC presents in its most common phenotype as dilated cardiomyopathy without having progressed through a restrictive phase is also unknown. Echocardiographic findings identify the consequences of iron overload on the myocardial structure and function but do not accurately predict myocardial iron content (54). Tissue Doppler-derived peak systolic strain has been shown to decrease early in this condition (55). Palka et al. (56) also reported a decrease in peak systolic and diastolic early filling mitral annular tissue velocity as well as prolongation of the duration of atrial reversal wave of pulmonary vein Doppler in early disease. Shizukuda et al. (57) have reported that enhanced left atrial active contraction can be observed before overt LV diastolic dysfunction appears, and may be the earliest detectable echocardiographic findings of cardiac iron overload. Strain rate imaging with speckle tracking can provide a more precise definition of local wall thickening and thinning leading to a better description of regional myocardial function. In patients with beta thalassemia, those with significant documented iron deposition had substantially lower longitudinal and circumferential early diastolic strain rate (58). Surprisingly, myocardial strain rate imaging may be a more sensitive measure of the effects of oxidative stress on LV diastolic dysfunction than a measure of overall iron content (59).

CMR is the only available noninvasive method with the potential to accurately quantitatively assess iron load (33,34,60). Iron's paramagnetic effect produces changes in the magnetic resonance signal intensity, shortens the T_2 weighted relaxation time, and darkens the image more quickly (**Figure 2**) (61,62). T_2 relaxation time is an excellent measure of myocardial iron deposition and is useful for serial assessment

JACC VOL. 71, NO. 10, 2018
MARCH 13, 2018:1149–66

FIGURE 2 Cardiac Magnetic Resonance Imaging of Iron-Overload Cardiomyopathy

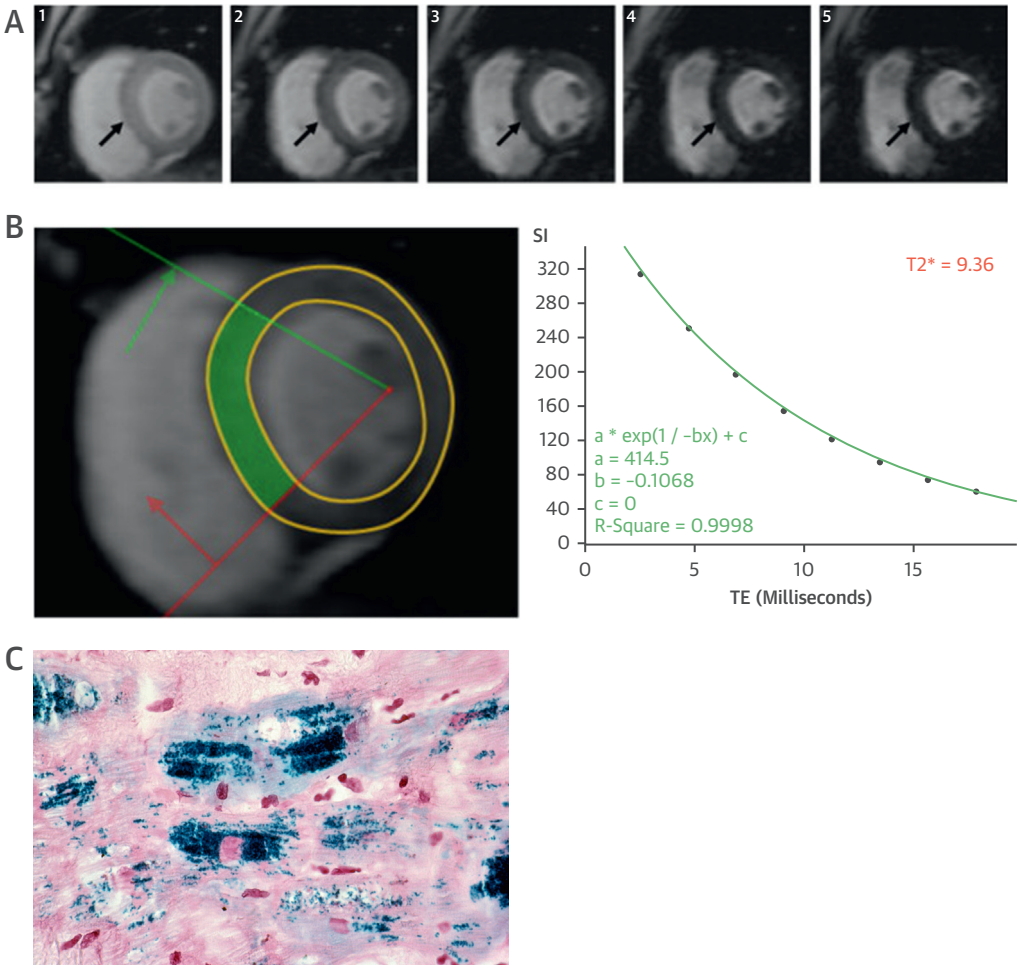

(A) Short-axis imaging demonstrates bright-blood T_2* sequence from a transfusion-dependent thalassemia patient. The myocardium is initially bright **(arrows),** but the signal delays quickly due to the high myocardial iron content. Reprinted with permission from Gupta A, Gulati GS, Seth S, Sharma S, et al. Cardiac MRI in restrictive cardiomyopathy. Clin Radiol 2012;67:95–105. **(B)** The calculated T_2* value is 9.4 ms, which is indicative of severe iron overload. **(C)** High-power photomicrograph of ventricular myocytes with extensive sarcoplasmic iron accumulation **(blue)** (Prussian blue stain; original magnification ×400). Image courtesy of Dr. Joseph Maleszewski, Mayo Clinic.

of response to iron chelation therapy. Measurements are performed in a full-thickness area of interest in the interventricular septum and are highly representative of global iron content. T_2 includes static magnetic field effects in addition to the tissue-characteristic T_2* relaxation, is distinct from T_2 imaging alone, and is more sensitive than T_2- or T_1-based imaging for IOC (63). Although myocardial T_2* has been shown to have no relationship to serum ferritin load, the T_2* relaxation time is mainly affected by iron in the form of hemosiderin and not by ferritin or labile cellular iron (64). Decreasing T_2* values, are correlated with increasing iron deposition and inversely correlated with global cardiac function. In RCM due to iron overload, T_2* values are typically <20 ms. A T_2* value <10 ms is indicative of severe iron overload and predicts subsequent risk of heart failure with a sensitivity of 97.5% and specificity of 83% (63). T_2* imaging has also been shown to be highly predictive of subsequent arrhythmia development (63). Studies designed to assess LV diastolic dysfunction in IOC with CMR using tagging techniques or displacement encoding with stimulated echocardiographic sequences are currently under active investigation (65,66).

Endomyocardial biopsy is no longer routinely utilized in the assessment of IOC. CMR has become the noninvasive procedure of choice for estimating overall myocardial iron content. Further, iron

deposition is heterogeneous, with the epicardium having the highest deposition of iron and thereby limiting the sensitivity and specificity of the biopsy (67).

TREATMENT. The mainstay of treatment for excessive iron deposition in patients with hemochromatosis is phlebotomy (33-35). Dietary intervention to decrease the consumption of iron-rich foods such as red meat generally has little effect on total body iron content. Alcohol increases iron absorption and its intake should be minimized (33). Multivitamin tablets containing iron and vitamin C should also be avoided. Phlebotomy removes 200 to 250 mg of iron at each session, and should be performed once or twice weekly to reduce serum ferritin <50 mg/ml and transferrin saturation <30%. After the therapeutic levels have been achieved, maintenance phlebotomy is undertaken to maintain a serum ferritin <100 mg/ml and transferrin saturation <50% (68). Improvements in cardiac function with RCM and arrhythmias have been noted if aggressive iron removal is initiated early in the disease process (69,70).

CHELATION THERAPY. Chelation therapy has been shown to be effective as an alternative option when phlebotomy is not feasible for patients who have IOC and chronic anemia or malignancy. In transfusion-dependent patients with MDS or other acquired hematological conditions, iron chelation therapy is generally initiated after 10 to 20 transfusions to prevent clinically significant myocardial iron deposition/accumulation (70). Three chelators are currently available: parenteral deferoxamine, and oral deferiprone and deferasirox (71). Early initiation of iron chelation treatment, particularly guided by serial CMR-T_2* imaging, has dramatically improved prognosis and survival, and can often prevent the development of iron overload cardiomyopathy, heart failure, and other complications (72). Patients with low to moderate cardiac iron deposition (T_2* values: 10 to 19 ms and without evidence for RCM) are generally treated with a single-drug chelation regimen to increase T_2* >20 ms (57,73,74). Combination therapy could be considered for patients with T_2* values of 10 to 15 ms (57,74). Finally, patients with marked cardiac iron deposition (T_2* <10 ms or documented either restrictive or dilated phenotypes) require intensive therapy, employing a combination of deferoxamine and deferiprone. In clinically unstable cases, continuous deferoxamine infusion to increase T_2* ≥20 ms should be administered and can improve cardiac performance (57,70). Finally, patients without evidence for myocardial iron deposition (T_2* >20 ms and normal echocardiographic function) should generally be treated with a single drug regimen to maintain T_2* ≥20 ms (57,74). Chelation therapy has been convincingly shown to improve systolic and diastolic ventricular function, prevent ventricular arrhythmias, and reduce mortality in patients with secondary forms of iron overload (42,43,75-78).

POTENTIAL NEW THERAPIES: ANTIOXIDANTS AND CALCIUM-CHANNEL ANTAGONISTS. Antioxidant treatment has theoretical appeal given the high degree of oxidative damage associated with IOC. In a murine model, taurine supplementation reduced myocardial iron burden, decreased iron-related oxidative damage, and provided protection of cardiac structure and function (79). Blockade of the L-type calcium channel decreases iron transport and may potentially reduce Fe^{2+}-induced Ca^{2+} overload (40). Calcium-channel antagonists also promote microvascular perfusion and improve coronary endothelial function; dihydropyridines such as amlodipine also possess antioxidant properties (33). Clinical trials have yet to be performed to establish the clinical efficacy and safety of calcium-channel blockade or antioxidant treatment.

Hepcidin is a 25 amino acid that plays a major role in regulating iron homeostasis. It is regulated by hemojuvelin, transferrin receptor-2, the protein encoded by the *HFE* gene, hypoxia, and inflammation (35). Decreased hepcidin levels have been noted in almost all iron overload diseases, and animal studies have demonstrated that administration of mini-hepcidins could prevent or treat iron overload; hence, hepcidin may prove to be a therapeutic target (80). Treatment of iron overload using hepcidin transcription inducers and hepcidin mimetic peptides or agonists is currently investigational (81).

Management of RCM and the restrictive cardiac phenotype due to iron overload has improved dramatically during the past decade primarily due to pre-emptive and early treatment guided by the use of CMR. A small minority of patients now progress to a dilated phenotype and overt symptomatic heart failure. Heart transplantation alone or with liver transplant has been rarely performed without disease recurrence, largely in those with IOC and primary hemochromatosis who have failed medical therapy. A 10-year actuarial survival rate of 41% has been reported in highly selected patients (82).

CARDIAC SARCOIDOSIS

Sarcoidosis is a multisystem, granulomatous disease of unknown etiology. Noncaseating granulomas are the pathological hallmark of the disease and are most

often associated with pulmonary and lymph node involvement; however, the heart is also frequently involved (83–86). The annual incidence of sarcoidosis in the United States is estimated at 10.9 per 100,000 in whites and 35.5 per 100,000 in African-Americans (86). Recent evidence suggests that sarcoidosis is caused by an immunological response to an unidentified antigenic trigger in genetically susceptible individuals (85). Disease prevalence demonstrates geographic, seasonal, and occupational clustering suggesting possible infectious, environmental, or occupational etiologies (87). Most disease (70%) occurs in patients between 25 and 60 years of age; it is rarely observed in patients <15 or >70 years of age (88).

GENETICS. Familial clustering indicates a strong genetic element in sarcoidosis (85,89). Associations have been described for a variety of genes including those associated with human leukocyte antigen (HLA), specifically HLA DQB1*0601 and HLA-DRB1*1101 (90,91). Among cytokine genes, tumor necrosis factor-308A and -857T polymorphisms have been shown to be strongly associated with sarcoid in Europeans (92). Alterations in immunoglobulin receptor genes, particularly splice mutations of BTNL2, have also been described (93).

CLINICAL FEATURES. Symptomatic cardiac involvement occurs in approximately 2% to 5% of patients with documented systemic sarcoidosis (87,94,95). However, the true prevalence of cardiac involvement is now estimated to exceed 25% of patients based upon recent CMR imaging studies (96). Isolated cardiac sarcoidosis, defined as cardiac involvement with no pre-existing diagnosis of extra pulmonary sarcoid or evidence of extracardiac sarcoid, accounts for 35% to 65% of all initial clinical presentations, including arrhythmias, cardiomyopathy, and abnormal cardiac imaging studies (97–100). Many of these patients will subsequently develop extracardiac sarcoidosis (101).

Clinical features of cardiac sarcoidosis depend on the location, extent, and activity of the granulomatous involvement within the myocardium disease (85). Thus, the clinical spectrum is highly varied and includes asymptomatic cardiac involvement, atrial or ventricular arrhythmias including sudden cardiac death (SCD), varying degrees of AV block, LV dysfunction (either restrictive [less common] or dilated [more common] phenotype), or overt heart failure (83–85).

Congestive heart failure is common in cardiac sarcoidosis and is present in 10% to 40% of reported series (83,102–104). This may result from several etiologies, including direct granulomatous infiltration of the myocardium, valvular regurgitation, or secondary right ventricular failure due to pulmonary involvement (105). Ventricular dysfunction may be due to systolic abnormalities, diastolic abnormalities, or both (83). Direct myocardial involvement may also lead to LV aneurysm formation. Mitral regurgitation, when present, is most often due to papillary muscle dysfunction but direct granulomatous involvement of the valves themselves may also occur (102–106).

Conduction system abnormalities are also commonly observed, ranging in prevalence from 12% to 62% of reported series (102–104). Complete heart block is the most common presenting conduction abnormality (25% to 30%) and most frequently presents as syncope (98,102,107). Complete heart block can occur without any evidence for cardiomyopathy or in the presence of early RCM (83). Finnish investigators confirmed the presence of cardiac sarcoidosis in 25% of patients age <55 years who presented with new-onset high-grade AV block (108).

Atrial arrhythmias are increasingly recognized as the first clinical manifestation of cardiac sarcoidosis (109). Supraventricular tachycardia occurs in approximately one-third of patients who develop arrhythmias. Several mechanisms have been proposed, including diastolic dysfunction and/or left atrial dilation secondary to LV systolic dysfunction or cor pulmonale (102). Granulomatous infiltration and scar formation within the atrium have been described, but are less commonly observed (102). Evidence of atrial late gadolinium enhancement on CMR is associated with 3-fold greater likelihood of developing symptomatic atrial arrhythmias over time (109).

Ventricular arrhythmias, including frequent premature ventricular complexes and ventricular tachycardia (VT), are also commonly observed, even in the presence of normal systolic function (84). More than two-thirds of ventricular arrhythmias are related to late-stage scar formation, with re-entrant scar-based circuits forming in areas of slow conduction (110,111). Sudden death is the most feared complication of cardiac sarcoidosis; unfortunately, SCD is responsible for up to 25% of initial presentations (84,102). Among patients with recurrent VT, nearly 50% are related to scar formation in the right ventricular or LV septal endocardium (112,113). Late gadolinium enhancement on CMR is associated with a substantially higher rate of VT recurrence despite antiarrhythmic or ablative therapy (114,115).

DIAGNOSTIC EVALUATION. Initial screening for suspected cardiac sarcoidosis should include detailed history and physical examination, an ECG, and a transthoracic echocardiogram. A positive history or significant ECG abnormality should prompt further

evaluation, usually with ambulatory ECG monitoring and additional imaging studies (83,103). The potential role of biomarkers, including B-type natriuretic peptide and cardiac troponin, in screening for cardiac sarcoidosis has met with disappointing results (116). Angiotensin-converting enzyme levels are elevated in approximate 60% of patients with active cardiac sarcoidosis; however, serum angiotensin-converting enzyme levels lack sensitivity and specificity for either diagnosing or managing the disease activity (117). Neopterin and, especially, soluble interleukin-2 receptor levels have been shown to be significantly elevated in active disease (118). However, no consensus exists on the optimal strategy or even whether serial diagnostic testing should occur in asymptomatic patients with known systemic sarcoidosis but without evidence for cardiac disease on initial screening (83). Mehta et al. (119) have reported a sensitivity of 100% and specificity of 87% for cardiac symptoms (palpitations, syncope, or presyncope) and/or an abnormal ECG, Holter monitor, or echocardiogram for detecting isolated cardiac sarcoidosis (119).

The ECG is usually abnormal in patients with clinically manifest cardiac disease (85). ECG patterns may demonstrate fragmentation of the QRS complex (75%), right bundle branch block (23%), left bundle branch block (3.8%), or varying degrees of heart block, the latter distinguishing cardiac sarcoidosis from other forms of cardiomyopathy (120,121). Rarely, pathologic Q waves or epsilon waves may occur (122). In contrast, the ECG is abnormal in only 3.2% to 8.6% of patients with clinically silent cardiac sarcoidosis as detected by CMR findings (123,124).

Echocardiography is an essential initial diagnostic study. Although it is often abnormal in overt symptomatic disease, it is usually normal in clinically silent cardiac sarcoidosis and in those patients who may present with SCD or ventricular arrhythmias (119). Echocardiographic abnormalities have been reported in 14% to 56% of patients (125,126). Findings are highly variable but are not specific for cardiac sarcoidosis (85). Left and/or right ventricular diastolic and systolic dysfunction, regional wall motion abnormalities, basal septal thickening, and discrete aneurysms are often observed (127). When present, regional wall motion abnormalities or myocardial thinning do not follow a typical coronary artery distribution. Smedema et al. (103) have reported that segmental wall motion abnormalities, extent of mitral regurgitation, LV dimensions, and both diastolic and systolic function correlate reasonably closely with the extent of myocardial involvement detected by CMR. However, in the same study, impaired diastolic relaxation was observed in 35% of patients without CMR evidence for cardiac sarcoidosis. Newer techniques, particularly myocardial strain rate imaging, show promise for detection of early disease, but are not specific for the presence of cardiac sarcoid (128).

CARDIAC MAGNETIC RESONANCE IMAGING. CMR has proven extremely useful in the initial diagnosis and subsequent follow-up of patients with cardiac sarcoidosis. Although T_2 imaging can identify myocardial edema associated with active inflammation, no specific pattern of late gadolinium enhancement (LGE) has been shown to be diagnostic for cardiac sarcoidosis; its distribution is usually patchy and multifocal with sparing of the endocardium (129,130). Two different mechanisms have been proposed for LGE. In the acute phase, it is believed to be due to focal myocarditis; in the chronic post-inflammatory phase, fibrosis is largely responsible (60,130,131). LGE is most commonly observed in the basal segments, particularly of the septum and lateral wall and usually in the midmyocardium and epicardium (**Figure 3**) (123,129). However, transmural involvement can rarely occur; further, the right ventricular free wall may also be involved in rare cases (123). Sensitivity and specificity rates of 76% to 100% and 78% to 92%, respectively, have been reported for diagnosing clinically suspected cardiac involvement (129,132).

CMR is increasingly utilized in evaluation of silent cardiac sarcoidosis in view of its ability to identify small regions of myocardial involvement in patients with preserved systolic function or early RCM (119,123,124). In addition to its diagnostic role, CMR has also assumed an increasing role in assessing risk for adverse cardiovascular events. The extent of LGE correlates reasonably well with the severity of cardiac involvement, due to both acute inflammation and cardiac fibrosis (133). Patients with significant LGE have been shown to have an increased risk of life-threatening ventricular arrhythmias and SCD with a reported hazard ratio of 31.6 for lethal events and 33.9 for all adverse cardiac events, independent of ejection fraction or LV volumes (114,134). Further, the extent of LGE has also been shown to be to predict corticosteroid responsiveness; a large LGE percentage being associated with lack of improvement in systolic function (135).

POSITRON EMISSION TOMOGRAPHIC IMAGING. Positron emission tomographic (PET) imaging with 18F-fluorodeoxyglucose (FDG) has been shown to correlate with histologic activity of sarcoidosis (83). FDG is a glucose analog that can differentiate between normal and active inflammatory lesions,

JACC VOL. 71, NO. 10, 2018
MARCH 13, 2018:1149–66

FIGURE 3 CMR and FDG-PET Imaging in Cardiac Sarcoidosis

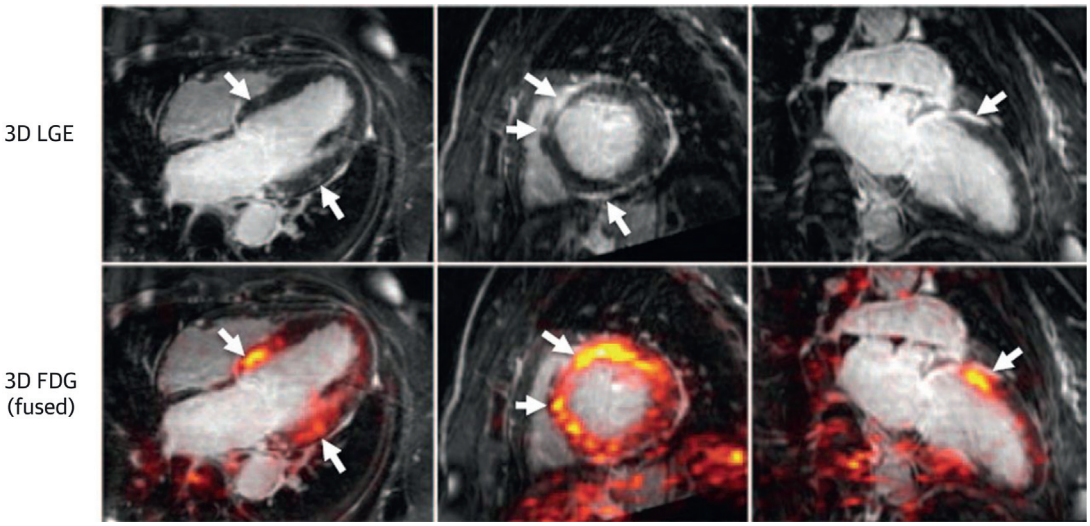

(Top) Representative 4-chamber, short-axis, and 2-chamber CMR views demonstrating abnormal LGE consistent with scarring. **(Bottom)** 3D-LGE images with fusion of FDG-PET signal demonstrating active inflammation surrounding regions of established scar formation. Reprinted with permission from White JA, Rajchl M, Butler J, Thompson RT, Prato FS, Wisenberg G. Active cardiac sarcoidosis: first clinical experience of simultaneous positron emission tomography-magnetic resonance imaging for the diagnosis of cardiac disease. Circulation 2013;127:e639-41. CMR = cardiac magnetic resonance imaging; FDG = fluorodeoxyglucose; LGE = late gadolinium enhancement; PET = positron emission tomography.

because activated pro-inflammatory macrophages demonstrate substantially higher metabolic rates and glucose utilization (136). Focal or focal plus diffuse FDG uptake patterns suggest active sarcoidosis (**Figure 3**) (137,138). PET imaging can provide both an accurate measure of disease activity using 18F-FDG uptake, as well as measurement of fibrotic replacement of the myocardium using perfusion imaging (139,140). The advantage of PET imaging compared with CMR is the ability to perform the test in patients with implantable cardioverter-defibrillators (ICDs) and its ability to distinguish active inflammation from scar. A recent meta-analysis reported an 89% sensitivity (range 79% to 100%) and a 78% specificity (range 38% to 100%) for 18F-FDG PET imaging in detecting active cardiac disease (139). One proposed explanation for the low sensitivity observed in some studies is the ability of this modality to detect subclinical disease (138). Several small case reports have also demonstrated that FDG uptake can be used to assess response to immunosuppressive treatment (141).

ENDOMYOCARDIAL BIOPSY. Endomyocardial biopsy is seldom indicated as it has a low sensitivity due to the focal nature of disease, revealing noncaseating granuloma in <25% of patients with subsequently proven cardiac sarcoidosis (100). It may occasionally be clinically indicated when extracardiac biopsies (e.g., lymph node or lung) are negative or for differentiating cardiac sarcoid from other forms of restrictive or inflammatory heart disease. Electroanatomic mapping (100,142) or image-guided PET- or CMR-directed biopsy (100) are now recommended by consensus guidelines (139,143). Intracardiac electrogram-guided biopsy has also been shown to increase the yield for detecting cardiac inflammatory diseases including cardiac sarcoidosis (142). These newer imaging techniques have increased the diagnostic yield of biopsies to approximately 50% (100,142).

TREATMENT AND PROGNOSIS. Immunosuppression. Management of cardiac sarcoidosis involves both immunosuppressive therapy as well as cardiac-specific treatments for ventricular dysfunction and heart rhythm abnormalities. In a Delphi study, sarcoid experts agreed on immunosuppressive therapy when there was evidence for LV systolic dysfunction, ventricular arrhythmias, hypermetabolic activity on cardiac 18F-FDG PET imaging, presence of conduction defects, delayed enhancement on CMR, or right ventricular dysfunction in the absence of pulmonary

hypertension (144). Its role in the treatment of restrictive physiology but preserved systolic function remains uncertain. Despite more than 50 years of use, there have been no randomized controlled trials of the efficacy of immunosuppressive treatment.

Immunosuppressive therapy appears to be beneficial for treatment of arrhythmias, both atrial and ventricular, that arise from active inflammation. Several uncontrolled studies have shown that corticosteroid therapy can also lead to resolution of second- or third-degree AV block (145,146). Treatment has also been shown to decrease the frequency of premature ventricular beats and may decrease the frequency of VT (147,148). Both clinical indications have received Class IIa recommendations in recent Heart Rhythm Society practice guidelines (148). The presence of normal LV systolic function (with or without diastolic dysfunction) predicts a good electrophysiological response to treatment (145,147).

The effect of corticosteroid treatment on LV systolic function has been reported in a variety of small, single-center observational studies (149). Among patients with normal LVEF (≥55%) or markedly reduced LVEF (<30%), LV systolic function did not typically improve with immunosuppressive therapy. However, patients with mildly to moderately reduced LV systolic function (LVEF 30% to 50%) who received immunosuppression generally demonstrate an improvement in LV systolic function (145,149). Although most studies of patients with severely reduced LVEF suggest a high scar burden and poor response to corticosteroid treatment, Kandolin et al. (97) have reported improvement in function among treated patients despite an initial LVEF <35%. The extent of LGE on CMR has been found to be predictive of corticosteroid response; a large extent of delayed enhancement has been associated with unfavorable response (134). Importantly, immunosuppressive therapy has also been shown to be associated with preservation of LV systolic function in patients with active cardiac sarcoidosis and normal LVEF at initiation of treatment (150). No data are available regarding their efficacy for improving diastolic function in the restrictive phenotype.

The choice and duration of corticosteroids also remains controversial (144). Several retrospective, uncontrolled studies have suggested that a corticosteroid dose of 30 mg daily tapered to a maintenance dose of 10 mg daily over a 6-month period appears to be effective (117,145-147,151). One study showed no significant difference in prognosis among patients treated with prednisone >40 mg daily compared with those treated with ≤30 mg daily (104). As expected, the effect of immunosuppressive therapy is dependent on baseline LV function—patients with LVEF >50% had higher response and survival rates than those who had LVEF <50% (152). Patients should be followed for at least 3 years by performing ECG and imaging studies after discontinuing treatment to assess for possible relapse (88). Methotrexate is used as a second-line agent in refractory cases and/or for its steroid-sparing effects (153); however, mycophenolate mofetil is more recently increasingly being used (154). Other treatments that have been used include azathioprine (155), cyclophosphamide (156), infliximab (157), adalimumab (158), and more recently, rituximab (159).

Management of arrhythmias and heart block. Patients who demonstrate second- or third-degree AV block require permanent pacemaker implantation, even if the AV block resolves during treatment (148). Implantation of an ICD is also recommended at the time of permanent pacer implantation because of the increased risk of sudden death in this population (148,160). Recent Heart Rhythm Society consensus guidelines recommended ICD implantation for all patients with sustained spontaneous ventricular arrhythmias and LVEF ≤35% despite optimal treatment, unexplained syncope, or inducible sustained ventricular arrhythmia on electrophysiological testing (148). Syncope is a particularly ominous symptom, because it can be caused by either high-grade heart block or life-threatening ventricular arrhythmias (83). Electrophysiological testing may be useful in this limited circumstance to differentiate potential etiologies and guide therapy. It is uncertain whether electrophysiological testing is a better predictor of future adverse cardiac events than LVEF alone, as the majority of events occur in patients with significant depression of LV function (161). Implantation of an ICD in patients with delayed enhancement on CMR but normal LVEF remains controversial and decision-making should be individualized. The vast majority of patients with normal LVEF rarely experience ventricular arrhythmias requiring ICD intervention; however, those with mildly depressed LVEF (35% to 49%) remain at increased risk for SCD (162,163). Conversely, the prevalence of ventricular arrhythmias in patients with preserved LVEF may be underestimated due to a failure to diagnose cardiac sarcoid in those patients who present with unexplained syncope or VT or SCD.

Although the most common mechanism of ventricular arrhythmias is macro-re-entry around an area of granulomatous scar, active inflammation may also play a role in promoting monomorphic VT due to re-entry, either by triggering it via ventricular ectopy

or by slowing conduction through diseased tissue (164). Antiarrhythmic therapy is generally ineffective. Immunosuppression may provide improvement in recurrent VT if active inflammation is present. VT ablation currently has a limited but evolving role in the management of recurrent VT that occurs after the acute inflammatory stage. Ablation outcomes are modest, reflecting the extensive scarring and multiple inducible morphologies that are encountered (85). Kumar et al. (164) reported VT-free survival of only 37% at 1 year; nonetheless, better VT control was achieved in the majority of patients with fewer antiarrhythmic drugs.

Prognosis. Patients with sarcoidosis who have cardiac involvement have a poorer prognosis than those without cardiac involvement. Mortality is usually due to progressive heart failure or sudden death. The extent of LV dysfunction is the most important predictor of survival (100,148). Kandolin et al. (100) have reported a 10-year transplant-free survival rate of 83%; heart failure at presentation predicted a poor outcome with a 10 event-free survival rate of only 53%. Conversely, Chiu et al. (150) found that all patients with normal LVEF (with or without diastolic dysfunction) were alive at 10 years (150). Eligible patients with end-stage heart failure with or without significant ventricular arrhythmias usually require heart transplantation and have a good prognosis (165). Cardiac transplantation has also been successfully performed in patients with refractory arrhythmias (166). Recurrence of cardiac sarcoidosis in the transplanted heart has been described within 6 months, but is rare and typically responds to enhanced immunosuppression (167). Finally, the prognosis of clinically silent cardiac sarcoidosis is uncertain. The majority of studies have reported a benign course (e.g., no cardiac events at an average follow-up of 23 months); however, several reports have documented SCD or symptomatic ventricular arrhythmias in this population (96,103,119,123,134).

RADIATION-INDUCED HEART DISEASE

Radiation-induced heart disease (RIHD) is becoming an increasing concern as use of radiotherapy increases and long-term cancer-free survival rates improve. Its manifestations are myriad and may include accelerated coronary artery disease, valvular dysfunction, RCM, aortopathy, and constrictive pericarditis (168). It had been recognized since the 1960s that substantial doses of radiation (>30 Gray [Gy]) that were initially employed during mantle radiotherapy for Hodgkin's lymphoma were cardiotoxic (169). However, convincing evidence has developed during the past decade that RIHD also occurs following doses substantially below 20 Gy (169). RIHD typically occurs with a latent period of 10 to 15 years (170). A large Scandinavian epidemiological study demonstrated a substantial increase in mortality from heart disease 15 years or more after radiation (hazard ratio: 1.27) (171). In a second study, radiation-related risk was studied by comparing women with left- and right-sided breast cancer; women with left-sided disease had greater cardiac radiation exposure and demonstrated higher rates of ischemic heart disease, pericarditis, and aortic valve disease (172). No difference in the risk for RCM was demonstrated between the 2 treatment groups. In a more contemporary era, a population-based, case-control study of incident heart failure in women who underwent radiotherapy for breast cancer and received a low mean cardiac radiation dose of 3.3 Gy, <20% of patients with HF experienced ischemic events, and a majority of patients had heart failure with preserved ejection fraction (173).

Radiation-related RCM is due to early inflammation, microvascular injury, and reduced capillary density, which lead to ischemia and myocyte replacement with diffuse bands of collagen replacement fibrosis (169,174). Clinical studies using single-photon emission computed tomography or PET imaging have demonstrated perfusion defects within 6 to 12 months after radiotherapy (169,175). Repeat myocardial perfusion imaging over 3 to 8 years after radiotherapy demonstrated persistent perfusion defects in the majority of patients (169). Radiation can also directly adversely affect diastolic function as seen in rats that received 10 or 20 Gy radiotherapy, resulting in reduced exercise capacity and elevated LV filling pressures (173). Histological analysis demonstrated increased cardiac fibrosis, cardiomyocyte hypertrophy, and reduced microvascular density (173).

Radiation-related myocardial fibrosis is often asymptomatic and is detected as an incidental finding on echocardiography more than 10 years after radiation therapy (176). Subclinical disease can be detected by strain rate imaging immediately after radiation therapy as myocardial strain is persistently decreased up to 14 months after treatment (177). Biochemical markers such as troponin are also elevated in the absence of overt cardiac dysfunction, especially in left-sided patients (177). In symptomatic patients, echocardiographic findings typically demonstrate normal or mildly impaired systolic function, normal ventricular wall thickness,

CENTRAL ILLUSTRATION Diagnostic Approach in Various Causes of Restrictive Cardiomyopathy When Patients Present With Heart Failure With Preserved Ejection

RESTRICTIVE CARDIOMYOPATHY (RCM)
A rare form of heart muscle disease characterized by rigid heart walls and restrictive filling of the ventricles

Age of Onset	Symptoms	Diagnostic Tools	Etiologies	Management
< 30 years of age (due largely to genetic abnormalities) **> 65 years of age**	No symptoms of RCM, or very mild symptoms Over time leads to heart failure that can cause symptoms of: Exercise intolerance Dyspnea Fatigue Arrhythmias Lower extremity edema	Medical history Echocardiogram MRI FDG-PET imaging Cardiac catheterization Endomyocardial biopsy **Important to rule out:** Hypertensive heart disease Hypertrophic cardiomyopathy Constrictive pericarditis High output heart failure	**Primary/idiopathic:** Endomyocardial fibrosis Idiopathic restrictive disease **Secondary/Infiltrative:** Amyloidosis Sarcoidosis Hemochromatosis Scleroderma Carcinoid heart disease Glycogen storage diseases such as Fabry disease Radiation induced Metastatic malignancy Iron overload	**Therapy is directed towards the specific underlying disease etiologies and to:** Relieve congestive symptoms (Loop diuretics, Sodium and fluid restriction) Rhythm control with the use of antiarrhythmic agents Permanent atrioventricular sequential pacer implantation Heart transplantation

Pereira, N.L. et al. J Am Coll Cardiol. 2018;71(10):1149–66.

FDG-PET = fluorodeoxyglucose positron emission tomography; MRI = magnetic resonance imaging; RCM = restrictive cardiomyopathy.

valvular calcification, impaired myocardial relaxation, and, in some patients, signs and symptoms suggesting pericardial constriction (178,179). RCM, although uncommon, is more likely to occur in the context of concomitant anthracycline chemotherapy or exposure to high radiation doses to large portions of the heart (169). Preventive measures can be undertaken to minimize toxicity due to radiation by using 3-dimensional imaging for treatment planning to minimize the dose and exposed cardiac contour, deep inspiration breath-hold techniques, robotic-directed delivery using a small linear particle accelerator, and using multiple or rotational sources of radiation beams (180). Clinical management of established disease is symptomatic and consists largely of diuretics to control volume overload. In advanced cases, cardiac transplantation has been successful in a limited number of radiation-induced RCM patients with actuarial survival rates in a single-center experience at 5 and 10 years of 75% and 47%, respectively (181). However, multicenter 5-year post-transplant survival reported in the United Network for Organ Sharing database was 58%, and was lower when compared with transplant for other types of RCM; this finding is likely related to the presence of concomitant mediastinal fibrosis and radiation lung disease, and prior cardiac surgeries leading to increased early post-operative deaths (182).

CONCLUSIONS

RCM comprises a heterogenous group of diseases that clinically manifests itself as heart failure with

preserved ejection fraction. The initial diagnostic approach is primarily based on echocardiographic findings, and individual disease entities can be further delineated by specific clinical, imaging, biochemical, and molecular characteristics as summarized in the **Central Illustration**. Considerable progress has been made in diagnosing and understanding the pathophysiology of the various causes of RCM over the past several decades, which has improved the treatment modalities available to the patient.

ADDRESS FOR CORRESPONDENCE: Dr. G. William Dec, Cardiology Division, Massachusetts General Hospital, 55 Fruit Street, Yawkey 5B, Boston, Massachusetts 01224. E-mail: gdec@parnters.org.

REFERENCES

1. Elliott P, Andersson B, Arbustini E, et al. Classification of the cardiomyopathies: a position statement from the European Society of Cardiology Working Group on Myocardial and Pericardial Diseases. Eur Heart J 2008;29:270–6.

2. Kushwaha SS, Fallon JT, Fuster V. Restrictive cardiomyopathy. N Engl J Med 1997;336:267–76.

3. Bhattacharyya S, Davar J, Dreyfus G, Caplin ME. Carcinoid heart disease. Circulation 2007;116:2860–5.

4. Grimaldi A, Mocumbi AO, Freers J, et al. Tropical endomyocardial fibrosis: natural history, challenges, and perspectives. Circulation 2016;133:2503–15.

5. Mocumbi AO, Ferreira MB, Sidi D, Yacoub MH. A population study of endomyocardial fibrosis in a rural area of Mozambique. N Engl J Med 2008;359:43–9.

6. Mocumbi AO, Yacoub S, Yacoub MH. Neglected tropical cardiomyopathies: II. Endomyocardial fibrosis: myocardial disease. Heart 2008;94:384–90.

7. Mocumbi AO, Latif N, Yacoub MH. Presence of circulating anti-myosin antibodies in endomyocardial fibrosis. PLoS Negl Trop Dis 2010;4:e661.

8. Mathai A, Kartha CC, Balakrishnan KG. Serum immunoglobulins in patients with endomyocardial fibrosis. Indian Heart J 1986;38:470–2.

9. Andy JJ, Ogunowo PO, Akpan NA, Odigwe CO, Ekanem IA, Esin RA. Helminth associated hypereosinophilia and tropical endomyocardial fibrosis (EMF) in Nigeria. Acta Trop 1998;69:127–40.

10. Teles FF. Chronic poisoning by hydrogen cyanide in cassava and its prevention in Africa and Latin America. Food Nutr Bull 2002;23:407–12.

11. Tharakan J, Bohora S. Current perspective on endomyocardial fibrosis. Curr Sci 2009;97:405–10.

12. Freers J, Mayanja-Kizza H, Rutakingirwa M, Gerwing E. Endomyocardial fibrosis: why is there striking ascites with little or no peripheral oedema? Lancet 1996;347:197.

13. Desser KB. Ascites in tropical endomyocardial fibrosis. Clin Cardiol 2007;30:634. author reply 634.

14. Tharakan JA. Electrocardiogram in endomyocardial fibrosis. Indian Pacing Electrophysiol J 2011;11:129–33.

15. Shaper AG, Wright DH. Intracardiac thrombosis and embolism in endomyocardial fibrosis in Uganda. Br Heart J 1963;25:502–8.

16. Berensztein CS, Pineiro D, Marcotegui M, Brunoldi R, Blanco MV, Lerman J. Usefulness of echocardiography and doppler echocardiography in endomyocardial fibrosis. J Am Soc Echocardiogr 2000;13:385–92.

17. Hassan WM, Fawzy ME, Al Helaly S, Hegazy H, Malik S. Pitfalls in diagnosis and clinical, echocardiographic, and hemodynamic findings in endomyocardial fibrosis: a 25-year experience. Chest 2005;128:3985–92.

18. Leon D, Martin M, Corros C, Santamarta E, Costilla S, Lambert JL. Usefulness of CMR in the early diagnosis of endomyocardial fibrosis. Rev Port Cardiol 2012;31:401–2.

19. Schneider U, Jenni R, Turina J, Turina M, Hess OM. Long-term follow up of patients with endomyocardial fibrosis: effects of surgery. Heart 1998;79:362–7.

20. Joshi R, Abraham S, Kumar AS. New approach for complete endocardiectomy in left ventricular endomyocardial fibrosis. J Thorac Cardiovasc Surg 2003;125:40–2.

21. Ino T, Benson LN, Freedom RM, Rowe RD. Natural history and prognostic risk factors in endocardial fibroelastosis. Am J Cardiol 1988;62:431–4.

22. Fathi AT, Dec GW Jr., Richter JM, et al. Case records of the Massachusetts General Hospital. Case 7-2014. A 27-year-old man with diarrhea, fatigue, and eosinophilia. N Engl J Med 2014;370:861–72.

23. Crane MM, Chang CM, Kobayashi MG, Weller PF. Incidence of myeloproliferative hypereosinophilic syndrome in the United States and an estimate of all hypereosinophilic syndrome incidence. J Allergy Clin Immunol 2010;126:179–81.

24. Weller PF, Bubley GJ. The idiopathic hypereosinophilic syndrome. Blood 1994;83:2759–79.

25. Cheah CY, Burbury K, Apperley JF, et al. Patients with myeloid malignancies bearing PDGFRB fusion genes achieve durable long-term remissions with imatinib. Blood 2014;123:3574–7.

26. Ommen SR, Seward JB, Tajik AJ. Clinical and echocardiographic features of hypereosinophilic syndromes. Am J Cardiol 2000;86:110–3.

27. Srichai MB, Junor C, Rodriguez LL, et al. Clinical, imaging, and pathological characteristics of left ventricular thrombus: a comparison of contrast-enhanced magnetic resonance imaging, transthoracic echocardiography, and transesophageal echocardiography with surgical or pathological validation. Am Heart J 2006;152:75–84.

28. Syed IS, Martinez MW, Feng DL, Glockner JF. Cardiac magnetic resonance imaging of eosinophilic endomyocardial disease. Int J Cardiol 2008;126:e50–2.

29. Moosbauer C, Morgenstern E, Cuvelier SL, et al. Eosinophils are a major intravascular location for tissue factor storage and exposure. Blood 2007;109:995–1002.

30. Ogbogu PU, Bochner BS, Butterfield JH, et al. Hypereosinophilic syndrome: a multicenter, retrospective analysis of clinical characteristics and response to therapy. J Allergy Clin Immunol 2009;124:1319–25.e3.

31. Butterfield JH, Weiler CR. Treatment of hypereosinophilic syndromes—the first 100 years. Semin Hematol 2012;49:182–91.

32. Boustany CW Jr., Murphy GW, Hicks GL Jr. Mitral valve replacement in idiopathic hypereosinophilic syndrome. Ann Thorac Surg 1991;51:1007–9.

33. Murphy CJ, Oudit GY. Iron-overload cardiomyopathy: pathophysiology, diagnosis, and treatment. J Card Fail 2010;16:888–900.

34. Gujja P, Rosing DR, Tripodi DJ, Shizukuda Y. Iron overload cardiomyopathy: betterunderstanding of an increasing disorder. J Am Coll Cardiol 2010;56:1001–12.

35. Kremastinos DT, Farmakis D. Iron overload cardiomyopathy in clinical practice. Circulation 2011;124:2253–63.

36. Andrews NC. Disorders of iron metabolism. N Engl J Med 1999;341:1986–95.

37. Eaton JW, Qian M. Molecular bases of cellular iron toxicity. Free Radic Biol Med 2002;32:833–40.

38. Oudit GY, Sun H, Trivieri MG, et al. L-type Ca2+ channels provide a major pathway for iron entry into cardiomyocytes in iron-overload cardiomyopathy. Nat Med 2003;9:1187–94.

39. Tsushima RG, Wickenden AD, Bouchard RA, Oudit GY, Liu PP, Backx PH. Modulation of iron uptake in heart by L-type Ca2+ channel modifiers: possible implications in iron overload. Circ Res 1999;84:1302–9.

40. Kremastinos DT, Tsiapras DP, Tsetsos GA, Rentoukas EI, Vretou HP, Toutouzas PK. Left ventricular diastolic Doppler characteristics in beta-thalassemia major. Circulation 1993;88:1127–35.

41. Liu P, Olivieri N. Iron overload cardiomyopathies: new insights into an old disease. Cardiovasc Drugs Ther 1994;8:101–10.

42. Olivieri NF, Nathan DG, MacMillan JH, et al. Survival in medically treated patients with homozygous beta-thalassemia. N Engl J Med 1994;331:574–8.

43. Brittenham GM, Griffith PM, Nienhuis AW, et al. Efficacy of deferoxamine in preventing complications of iron overload in patients with thalassemia major. N Engl J Med 1994;331:567–73.

44. Spirito P, Lupi G, Melevendi C, Vecchio C. Restrictive diastolic abnormalities identified by Doppler echocardiography in patients with thalassemia major. Circulation 1990;82:88–94.

45. Lubitz SA, Goldbarg SH, Mehta D. Sudden cardiac death in infiltrative cardiomyopathies: sarcoidosis, scleroderma, amyloidosis, hemachromatosis. Prog Cardiovasc Dis 2008;51:58–73.

46. Palka P, Macdonald G, Lange A, Burstow DJ. The role of Doppler left ventricular filling indexes and Doppler tissue echocardiography in the assessment of cardiac involvement in hereditary hemochromatosis. J Am Soc Echocardiogr 2002;15:884–90.

47. Kremastinos DT, Tsiapras DP, Kostopoulou AG, Hamodraka ES, Chaidaroglou AS, Kapsali ED. NT-proBNP levels and diastolic dysfunction in beta-thalassaemia major patients. Eur J Heart Fail 2007;9:531–6.

48. Kremastinos DT, Hamodraka E, Parissis J, Tsiapras D, Dima K, Maisel A. Predictive value of B-type natriuretic peptides in detecting latent left ventricular diastolic dysfunction in beta-thalassemia major. Am Heart J 2010;159:68–74.

49. Kremastinos DT. Heart failure in beta-thalassemia. Congest Heart Fail 2001;7:312–4.

50. Qaseem A, Aronson M, Fitterman N, Snow V, Weiss KB, Owens DK. Screening for hereditary hemochromatosis: a clinical practice guideline from the American College of Physicians. Ann Intern Med 2005;143:517–21.

51. Beutler E, Felitti V, Gelbart T, Ho N. The effect of HFE genotypes on measurements of iron overload in patients attending a health appraisal clinic. Ann Intern Med 2000;133:329–37.

52. Machado RF, Anthi A, Steinberg MH, et al. N-terminal pro-brain natriuretic peptide levels and risk of death in sickle cell disease. JAMA 2006;296:310–8.

53. Isma'eel H, Chafic AH, El Rassi F, et al. Relation between iron-overload indices, cardiac echo-Doppler, and biochemical markers in thalassemia intermedia. Am J Cardiol 2008;102:363–7.

54. Kremastinos DT, Farmakis D, Aessopos A, et al. Beta-thalassemia cardiomyopathy: history, present considerations, and future perspectives. Circ Heart Fail 2010;3:451–8.

55. Hamdy AM. Use of strain and tissue velocity imaging for early detection of regional myocardial dysfunction in patients with beta thalassemia. Eur J Echocardiogr 2007;8:102–9.

56. Palka P, Lange A, Atherton J, Stafford WJ, Burstow DJ. Biventricular diastolic behaviour in patients with hypertrophic and hereditary hemochromatosis cardiomyopathies. Eur J Echocardiogr 2004;5:356–66.

57. Shizukuda Y, Bolan CD, Tripodi DJ, et al. Significance of left atrial contractile function in asymptomatic subjects with hereditary hemochromatosis. Am J Cardiol 2006;98:954–9.

58. Abraham TP, Dimaano VL, Liang HY. Role of tissue Doppler and strain echocardiography in current clinical practice. Circulation 2007;116:2597–609.

59. Shizukuda Y, Bolan CD, Tripodi DJ, et al. Does oxidative stress modulate left ventricular diastolic function in asymptomatic subjects with hereditary hemochromatosis? Echocardiography 2009;26:1153–8.

60. Cheng H, Zhao S, Jiang S, et al. The relative atrial volume ratio and late gadolinium enhancement provide additive information to differentiate constrictive pericarditis from restrictive cardiomyopathy. J Cardiovasc Magn Reson 2011;13:15.

61. Anderson LJ, Holden S, Davis B, et al. Cardiovascular T2-star (T2*) magnetic resonance for the early diagnosis of myocardial iron overload. Eur Heart J 2001;22:2171–9.

62. Kondur AK, Li T, Vaitkevicius P, Afonso L. Quantification of myocardial iron overload by cardiovascular magnetic resonance imaging T2* and review of the literature. Clin Cardiol 2009;32:E55–9.

63. Kirk P, Roughton M, Porter JB, et al. Cardiac T2* magnetic resonance for prediction of cardiac complications in thalassemia major. Circulation 2009;120:1961–8.

64. Wood JC. History and current impact of cardiac magnetic resonance imaging on the management of iron overload. Circulation 2009;120:1937–9.

65. Reichek N. MRI myocardial tagging. J Magn Reson Imaging 1999;10:609–16.

66. Aletras AH, Ingkanisorn WP, Mancini C, Arai AE. DENSE with SENSE. J Magn Reson 2005;176:99–106.

67. Barosi G, Arbustini E, Gavazzi A, Grasso M, Pucci A. Myocardial iron grading by endomyocardial biopsy. A clinico-pathologic study on iron overloaded patients. Eur J Haematol 1989;42:382–8.

68. Pietrangelo A. Hereditary hemochromatosis—a new look at an old disease. N Engl J Med 2004;350:2383–97.

69. Candell-Riera J, Lu L, Seres L, et al. Cardiac hemochromatosis: beneficial effects of iron removal therapy. An echocardiographic study. Am J Cardiol 1983;52:824–9.

70. Rivers J, Garrahy P, Robinson W, Murphy A. Reversible cardiac dysfunction in hemochromatosis. Am Heart J 1987;113:216–7.

71. Brittenham GM. Iron-chelating therapy for transfusional iron overload. N Engl J Med 2011;364:146–56.

72. Modell B, Khan M, Darlison M, Westwood MA, Ingram D, Pennell DJ. Improved survival of thalassaemia major in the UK and relation to T2* cardiovascular magnetic resonance. J Cardiovasc Magn Reson 2008;10:42.

73. Aessopos A, Berdoukas V, Tsironi M. The heart in transfusion dependent homozygous thalassaemia today—prediction, prevention and management. Eur J Haematol 2008;80:93–106.

74. Aessopos A, Kati M, Farmakis D, Polonifi E, Deftereos S, Tsironi M. Intensive chelation therapy in beta-thalassemia and possible adverse cardiac effects of desferrioxamine. Int J Hematol 2007;86:212–5.

75. Anderson LJ, Westwood MA, Holden S, et al. Myocardial iron clearance during reversal of siderotic cardiomyopathy with intravenous desferrioxamine: a prospective study using T2* cardiovascular magnetic resonance. Br J Haematol 2004;127:348–55.

76. Pennell DJ, Porter JB, Cappellini MD, et al. Efficacy of deferasirox in reducing and preventing cardiac iron overload in beta-thalassemia. Blood 2010;115:2364–71.

77. Pennell DJ, Berdoukas V, Karagiorga M, et al. Randomized controlled trial of deferiprone or deferoxamine in beta-thalassemia major patients with asymptomatic myocardial siderosis. Blood 2006;107:3738–44.

78. Tanner MA, Galanello R, Dessi C, et al. A randomized, placebo-controlled, double-blind trial of the effect of combined therapy with deferoxamine and deferiprone on myocardial iron in thalassemia major using cardiovascular magnetic resonance. Circulation 2007;115:1876–84.

79. Oudit GY, Trivieri MG, Khaper N, et al. Taurine supplementation reduces oxidative stress and improves cardiovascular function in an iron-overload murine model. Circulation 2004;109:1877–85.

80. Ramos E, Ruchala P, Goodnough JB, et al. Minihepcidins prevent iron overload in a hepcidin-deficient mouse model of severe hemochromatosis. Blood 2012;120:3829–36.

81. Crielaard BJ, Lammers T, Rivella S. Targeting iron metabolism in drug discovery and delivery. Nat Rev Drug Discov 2017;16:400–23.

82. Caines AE, Kpodonu J, Massad MG, et al. Cardiac transplantation in patients with iron overload cardiomyopathy. J Heart Lung Transplant 2005;24:486–8.

83. Kim JS, Judson MA, Donnino R, et al. Cardiac sarcoidosis. Am Heart J 2009;157:9–21.

84. Hamzeh N, Steckman DA, Sauer WH, Judson MA. Pathophysiology and clinical management of cardiac sarcoidosis. Nat Rev Cardiol 2015;12:278–88.

85. Birnie DH, Nery PB, Ha AC, Beanlands RS. Cardiac sarcoidosis. J Am Coll Cardiol 2016;68:411–21.

86. Rybicki BA, Major M, Popovich J Jr., Maliarik MJ, Iannuzzi MC. Racial differences in sarcoidosis incidence: a 5-year study in a health maintenance organization. Am J Epidemiol 1997;145:234–41.

87. Perry A, Vuitch F. Causes of death in patients with sarcoidosis. A morphologic study of 38 autopsies with clinicopathologic correlations. Arch Pathol Lab Med 1995;119:167–72.

88. Valeyre D, Prasse A, Nunes H, Uzunhan Y, Brillet PY, Muller-Quernheim J. Sarcoidosis. Lancet 2014;383:1155–67.

89. Rybicki BA, Iannuzzi MC, Frederick MM, et al. Familial aggregation of sarcoidosis. A case-control etiologic study of sarcoidosis (ACCESS). Am J Respir Crit Care Med 2001;164:2085–91.

90. Naruse TK, Matsuzawa Y, Ota M, et al. HLA-DQB1*0601 is primarily associated with the susceptibility to cardiac sarcoidosis. Tissue Antigens 2000;56:52–7.

91. Rossman MD, Thompson B, Frederick M, et al. HLA-DRB1*1101: a significant risk factor for sarcoidosis in blacks and whites. Am J Hum Genet 2003;73:720–35.

92. Grutters JC, Sato H, Pantelidis P, et al. Increased frequency of the uncommon tumor necrosis factor-857T allele in British and Dutch patients with sarcoidosis. Am J Respir Crit Care Med 2002;165:1119–24.

93. Valentonyte R, Hampe J, Huse K, et al. Sarcoidosis is associated with a truncating splice site mutation in BTNL2. Nat Genet 2005;37:357–64.

94. Baughman RP, Teirstein AS, Judson MA, et al. Clinical characteristics of patients in a case control study of sarcoidosis. Am J Respir Crit Care Med 2001;164:1885–9.

95. Roberts WC, Chung MS, Ko JM, Capehart JE, Hall SA. Morphologic features of cardiac sarcoidosis in native hearts of patients having cardiac transplantation. Am J Cardiol 2014;113:706–12.

96. Murtagh G, Laffin LJ, Beshai JF, et al. Prognosis of myocardial damage in sarcoidosis patients with preserved left ventricular ejection fraction: risk stratification using cardiovascular magnetic resonance. Circ Cardiovasc Imaging 2016;9:e003738.

97. Kandolin R, Lehtonen J, Airaksinen J, et al. Cardiac sarcoidosis: epidemiology, characteristics, and outcome over 25 years in a nationwide study. Circulation 2015;131:624–32.

98. Nery PB, Beanlands RS, Nair GM, et al. Atrioventricular block as the initial manifestation of cardiac sarcoidosis in middle-aged adults. J Cardiovasc Electrophysiol 2014;25:875–81.

99. Nery PB, Mc Ardle BA, Redpath CJ, et al. Prevalence of cardiac sarcoidosis in patients presenting with monomorphic ventricular tachycardia. Pacing Clin Electrophysiol 2014;37:364–74.

100. Kandolin R, Lehtonen J, Graner M, et al. Diagnosing isolated cardiac sarcoidosis. J Intern Med 2011;270:461–8.

101. Nelson JE, Kirschner PA, Teirstein AS. Sarcoidosis presenting as heart disease. Sarcoidosis Vasc Diffuse Lung Dis 1996;13:178–82.

102. Roberts WC, McAllister HA Jr., Ferrans VJ. Sarcoidosis of the heart. A clinicopathologic study of 35 necropsy patients (group 1) and review of 78 previously described necropsy patients (group 11). Am J Med 1977;63:86–108.

103. Smedema JP, Snoep G, van Kroonenburgh MP, et al. Cardiac involvement in patients with pulmonary sarcoidosis assessed at two university medical centers in the Netherlands. Chest 2005;128:30–5.

104. Yazaki Y, Isobe M, Hiroe M, et al. Prognostic determinants of long-term survival in Japanese patients with cardiac sarcoidosis treated with prednisone. Am J Cardiol 2001;88:1006–10.

105. Cooper LT Jr. Giant cell and granulomatous myocarditis. Heart Fail Clin 2005;1:431–7.

106. Gasparovic H, Bueno R, Rybicki FJ, et al. Sarcoidosis of the aortic root. J Thorac Cardiovasc Surg 2004;128:761–2.

107. Yoshida Y, Morimoto S, Hiramitsu S, Tsuboi N, Hirayama H, Itoh T. Incidence of cardiac sarcoidosis in Japanese patients with high-degree atrioventricular block. Am Heart J 1997;134:382–6.

108. Kandolin R, Lehtonen J, Kupari M. Cardiac sarcoidosis and giant cell myocarditis as causes of atrioventricular block in young and middle-aged adults. Circ Arrhythm Electrophysiol 2011;4:303–9.

109. Cain MA, Metzl MD, Patel AR, et al. Cardiac sarcoidosis detected by late gadolinium enhancement and prevalence of atrial arrhythmias. Am J Cardiol 2014;113:1556–60.

110. Winters SL, Cohen M, Greenberg S, et al. Sustained ventricular tachycardia associated with sarcoidosis: assessment of the underlying cardiac anatomy and the prospective utility of programmed ventricular stimulation, drug therapy and an implantable antitachycardia device. J Am Coll Cardiol 1991;18:937–43.

111. Koplan BA, Soejima K, Baughman K, Epstein LM, Stevenson WG. Refractory ventricular tachycardia secondary to cardiac sarcoid: electrophysiologic characteristics, mapping, and ablation. Heart Rhythm 2006;3:924–9.

112. Uusimaa P, Ylitalo K, Anttonen O, et al. Ventricular tachyarrhythmia as a primary presentation of sarcoidosis. Europace 2008;10:760–6.

113. Naruse Y, Sekiguchi Y, Nogami A, et al. Systematic treatment approach to ventricular tachycardia in cardiac sarcoidosis. Circ Arrhythm Electrophysiol 2014;7:407–13.

114. Crawford T, Mueller G, Sarsam S, et al. Magnetic resonance imaging for identifying patients with cardiac sarcoidosis and preserved or mildly reduced left ventricular function at risk of ventricular arrhythmias. Circ Arrhythm Electrophysiol 2014;7:1109–15.

115. Shafee MA, Fukuda K, Wakayama Y, et al. Delayed enhancement on cardiac magnetic resonance imaging is a poor prognostic factor in patients with cardiac sarcoidosis. J Cardiol 2012;60:448–53.

116. Kandolin R, Lehtonen J, Airaksinen J, et al. Usefulness of cardiac troponins as markers of early treatment response in cardiac sarcoidosis. Am J Cardiol 2015;116:960–4.

117. Iannuzzi MC, Rybicki BA, Teirstein AS. Sarcoidosis. N Engl J Med 2007;357:2153–65.

118. Vorselaars AD, van Moorsel CH, Zanen P, et al. ACE and sIL-2R correlate with lung function improvement in sarcoidosis during methotrexate therapy. Respir Med 2015;109:279–85.

119. Mehta D, Lubitz SA, Frankel Z, et al. Cardiac involvement in patients with sarcoidosis: diagnostic and prognostic value of outpatient testing. Chest 2008;133:1426–35.

120. Schuller JL, Olson MD, Zipse MM, et al. Electrocardiographic characteristics in patients with pulmonary sarcoidosis indicating cardiac involvement. J Cardiovasc Electrophysiol 2011;22:1243–8.

121. Homsi M, Alsayed L, Safadi B, Mahenthiran J, Das MK. Fragmented QRS complexes on 12-lead ECG: a marker of cardiac sarcoidosis as detected by gadolinium cardiac magnetic resonance imaging. Ann Noninvasive Electrocardiol 2009;14:319–26.

122. Nery PB, Keren A, Healey J, Leug E, Beanlands RS, Birnie DH. Isolated cardiac sarcoidosis: establishing the diagnosis with electroanatomic mapping-guided endomyocardial biopsy. Can J Cardiol 2013;29:1015.e1–3.

123. Patel MR, Cawley PJ, Heitner JF, et al. Detection of myocardial damage in patients with sarcoidosis. Circulation 2009;120:1969–77.

124. Pizarro C, Goebel A, Dabir D, et al. Cardiovascular magnetic resonance-guided diagnosis of cardiac affection in a Caucasian sarcoidosis population. Sarcoidosis Vasc Diffuse Lung Dis 2016;32:325–35.

125. Fahy GJ, Marwick T, McCreery CJ, Quigley PJ, Maurer BJ. Doppler echocardiographic detection of left ventricular diastolic dysfunction in patients with pulmonary sarcoidosis. Chest 1996;109:62–6.

126. Hyodo E, Hozumi T, Takemoto Y, et al. Early detection of cardiac involvement in patients with sarcoidosis by a non-invasive method with ultrasonic tissue characterisation. Heart 2004;90:1275–80.

127. Skold CM, Larsen FF, Rasmussen E, Pehrsson SK, Eklund AG. Determination of cardiac involvement in sarcoidosis by magnetic resonance imaging and Doppler echocardiography. J Intern Med 2002;252:465–71.

128. Joyce E, Ninaber MK, Katsanos S, et al. Subclinical left ventricular dysfunction by echocardiographic speckle-tracking strain analysis relates to outcome in sarcoidosis. Eur J Heart Fail 2015;17:51–62.

129. Smedema JP, Snoep G, van Kroonenburgh MP, et al. Evaluation of the accuracy of gadolinium-enhanced cardiovascular magnetic resonance in the diagnosis of cardiac sarcoidosis. J Am Coll Cardiol 2005;45:1683–90.

130. Vignaux O. Cardiac sarcoidosis: spectrum of MRI features. AJR Am J Roentgenol 2005;184:249–54.

131. Ichinose A, Otani H, Oikawa M, et al. MRI of cardiac sarcoidosis: basal and subepicardial localization of myocardial lesions and their effect on left ventricular function. AJR Am J Roentgenol 2008;191:862–9.

132. Yoshida A, Ishibashi-Ueda H, Yamada N, et al. Direct comparison of the diagnostic capability of cardiac magnetic resonance and endomyocardial biopsy in patients with heart failure. Eur J Heart Fail 2013;15:166–75.

133. Vignaux O, Dhote R, Duboc D, et al. Clinical significance of myocardial magnetic resonance abnormalities in patients with sarcoidosis: a 1-year follow-up study. Chest 2002;122:1895–901.

134. Greulich S, Deluigi CC, Gloekler S, et al. CMR imaging predicts death and other adverse events in suspected cardiac sarcoidosis. J Am Coll Cardiol Img 2013;6:501–11.

135. Ise T, Hasegawa T, Morita Y, et al. Extensive late gadolinium enhancement on cardiovascular magnetic resonance predicts adverse outcomes and lack of improvement in LV function after steroid therapy in cardiac sarcoidosis. Heart 2014;100:1165–72.

136. Pellegrino D, Bonab AA, Dragotakes SC, Pitman JT, Mariani G, Carter EA. Inflammation and infection: imaging properties of 18F-FDG-labeled white blood cells versus 18F-FDG. J Nucl Med 2005;46:1522–30.

137. Ishimaru S, Tsujino I, Takei T, et al. Focal uptake on 18F-fluoro-2-deoxyglucose positron emission tomography images indicates cardiac involvement of sarcoidosis. Eur Heart J 2005;26:1538–43.

138. Youssef G, Leung E, Mylonas I, et al. The use of 18F-FDG PET in the diagnosis of cardiac sarcoidosis: a systematic review and metaanalysis including the Ontario experience. J Nucl Med 2012;53:241–8.

139. Yamagishi H, Shirai N, Takagi M, et al. Identification of cardiac sarcoidosis with (13)N-NH(3)/(18)F-FDG PET. J Nucl Med 2003;44:1030–6.

140. Okumura W, Iwasaki T, Toyama T, et al. Usefulness of fasting 18F-FDG PET in identification of cardiac sarcoidosis. J Nucl Med 2004;45:1989–98.

141. Tadamura E, Yamamuro M, Kubo S, et al. Images in cardiovascular medicine. Multimodality imaging of cardiac sarcoidosis before and after steroid therapy. Circulation 2006;113:e771–3.

142. Liang JJ, Hebl VB, DeSimone CV, et al. Electrogram guidance: a method to increase the precision and diagnostic yield of endomyocardial biopsy for suspected cardiac sarcoidosis and myocarditis. J Am Coll Cardiol HF 2014;2:466–73.

143. Leone O, Veinot JP, Angelini A, et al. 2011 consensus statement on endomyocardial biopsy from the Association for European Cardiovascular Pathology and the Society for Cardiovascular Pathology. Cardiovasc Pathol 2012;21:245–74.

144. Hamzeh NY, Wamboldt FS, Weinberger HD. Management of cardiac sarcoidosis in the United States: a Delphi study. Chest 2012;141:154–62.

145. Yodogawa K, Seino Y, Shiomura R, et al. Recovery of atrioventricular block following steroid therapy in patients with cardiac sarcoidosis. J Cardiol 2013;62:320–5.

146. Kato Y, Morimoto S, Uemura A, Hiramitsu S, Ito T, Hishida H. Efficacy of corticosteroids in sarcoidosis presenting with atrioventricular block. Sarcoidosis Vasc Diffuse Lung Dis 2003;20:133–7.

147. Yodogawa K, Seino Y, Ohara T, Takayama H, Katoh T, Mizuno K. Effect of corticosteroid therapy on ventricular arrhythmias in patients with cardiac sarcoidosis. Ann Noninvasive Electrocardiol 2011;16:140–7.

148. Birnie DH, Sauer WH, Bogun F, et al. HRS expert consensus statement on the diagnosis and management of arrhythmias associated with cardiac sarcoidosis. Heart Rhythm 2014;11:1305–23.

149. Sadek MM, Yung D, Birnie DH, Beanlands RS, Nery PB. Corticosteroid therapy for cardiac sarcoidosis: a systematic review. Can J Cardiol 2013;29:1034–41.

150. Chiu CZ, Nakatani S, Zhang G, et al. Prevention of left ventricular remodeling by long-term corticosteroid therapy in patients with cardiac sarcoidosis. Am J Cardiol 2005;95:143–6.

151. Banba K, Kusano KF, Nakamura K, et al. Relationship between arrhythmogenesis and disease activity in cardiac sarcoidosis. Heart Rhythm 2007;4:1292–9.

152. Grutters JC, van den Bosch JM. Corticosteroid treatment in sarcoidosis. Eur Respir J 2006;28:627–36.

153. Nagai S, Yokomatsu T, Tanizawa K, et al. Treatment with methotrexate and low-dose corticosteroids in sarcoidosis patients with cardiac lesions. Intern Med 2014;53:2761.

154. Hamzeh N, Voelker A, Forssen A, et al. Efficacy of mycophenolate mofetil in sarcoidosis. Respir Med 2014;108:1663–9.

155. Muller-Quernheim J, Kienast K, Held M, Pfeifer S, Costabel U. Treatment of chronic sarcoidosis with an azathioprine/prednisolone regimen. Eur Respir J 1999;14:1117–22.

156. Demeter SL. Myocardial sarcoidosis unresponsive to steroids. Treatment with cyclophosphamide. Chest 1988;94:202–3.

157. Judson MA, Baughman RP, Costabel U, et al. Efficacy of infliximab in extrapulmonary sarcoidosis: results from a randomised trial. Eur Respir J 2008;31:1189–96.

158. Crommelin HA, van der Burg LM, Vorselaars ADM, et al. Efficacy of adalimumab in sarcoidosis patients who developed intolerance to infliximab. Respir Med 2016;115:72–7.

159. Cinetto F, Compagno N, Scarpa R, Malipiero G, Agostini C. Rituximab in refractory sarcoidosis: a single centre experience. Clin Mol Allergy 2015;13:19.

160. Epstein AE, DiMarco JP, Ellenbogen KA, et al. 2012 ACCF/AHA/HRS focused update incorporated into the ACCF/AHA/HRS 2008 guidelines for device-based therapy of cardiac rhythm abnormalities: a report of the American College of Cardiology Foundation/American Heart Association Task Force on Practice Guidelines and the Heart Rhythm Society. J Am Coll Cardiol 2013;61:e6–75.

161. Mehta D, Mori N, Goldbarg SH, Lubitz S, Wisnivesky JP, Teirstein A. Primary prevention of sudden cardiac death in silent cardiac sarcoidosis: role of programmed ventricular stimulation. Circ Arrhythm Electrophysiol 2011;4:43–8.

162. Schuller JL, Zipse M, Crawford T, et al. Implantable cardioverter defibrillator therapy in patients with cardiac sarcoidosis. J Cardiovasc Electrophysiol 2012;23:925–9.

163. Kron J, Sauer W, Schuller J, et al. Efficacy and safety of implantable cardiac defibrillators for treatment of ventricular arrhythmias in patients with cardiac sarcoidosis. Europace 2013;15:347–54.

164. Kumar S, Barbhaiya C, Nagashima K, et al. Ventricular tachycardia in cardiac sarcoidosis: characterization of ventricular substrate and outcomes of catheter ablation. Circ Arrhythm Electrophysiol 2015;8:87–93.

165. Perkel D, Czer LS, Morrissey RP, et al. Heart transplantation for end-stage heart failure due to cardiac sarcoidosis. Transplant Proc 2013;45:2384–6.

166. Zaidi AR, Zaidi A, Vaitkus PT. Outcome of heart transplantation in patients with sarcoid cardiomyopathy. J Heart Lung Transplant 2007;26:714–7.

167. Yager JE, Hernandez AF, Steenbergen C, et al. Recurrence of cardiac sarcoidosis in a heart transplant recipient. J Heart Lung Transplant 2005;24:1988–90.

168. Zhuang XF, Yang YM, Sun XL, Liao ZK, Huang J. Late onset radiation-induced constrictive pericarditis and cardiomyopathy after radiotherapy: a case report. Medicine (Baltimore) 2017;96:e5932.

169. Darby SC, Cutter DJ, Boerma M, et al. Radiation-related heart disease: current knowledge and future prospects. Int J Radiat Oncol Biol Phys 2010;76:656–65.

170. Andratschke N, Maurer J, Molls M, Trott KR. Late radiation-induced heart disease after radiotherapy. Clinical importance, radiobiological mechanisms and strategies of prevention. Radiother Oncol 2011;100:160–6.

171. Clarke M, Collins R, Darby S, et al. Effects of radiotherapy and of differences in the extent of surgery for early breast cancer on local recurrence and 15-year survival: an overview of the randomised trials. Lancet 2005;366:2087–106.

172. McGale P, Darby SC, Hall P, et al. Incidence of heart disease in 35,000 women treated with radiotherapy for breast cancer in Denmark and Sweden. Radiother Oncol 2011;100:167–75.

173. Saiki H, Petersen IA, Scott CG, et al. Risk of heart failure with preserved ejection fraction in older women after contemporary radiotherapy for breast cancer. Circulation 2017;135:1388–96.

174. Chello M, Mastroroberto P, Romano R, Zofrea S, Bevacqua I, Marchese AR. Changes in the proportion of types I and III collagen in the left ventricular wall of patients with post-irradiative pericarditis. Cardiovasc Surg 1996;4:222–6.

175. Prosnitz RG, Hubbs JL, Evans ES, et al. Prospective assessment of radiotherapy-associated cardiac toxicity in breast cancer patients: analysis of data 3 to 6 years after treatment. Cancer 2007;110:1840–50.

176. Heidenreich PA, Hancock SL, Lee BK, Mariscal CS, Schnittger I. Asymptomatic cardiac disease following mediastinal irradiation. J Am Coll Cardiol 2003;42:743–9.

177. Erven K, Florian A, Slagmolen P, et al. Subclinical cardiotoxicity detected by strain rate imaging up to 14 months after breast radiation therapy. Int J Radiat Oncol Biol Phys 2013;85:1172–8.

178. Adams MJ, Lipsitz SR, Colan SD, et al. Cardiovascular status in long-term survivors of Hodgkin's disease treated with chest radiotherapy. J Clin Oncol 2004;22:3139–48.

JACC VOL. 71, NO. 10, 2018
MARCH 13, 2018:1149–66

179. Lancellotti P, Nkomo VT, Badano LP, et al. Expert consensus for multi-modality imaging evaluation of cardiovascular complications of radiotherapy in adults: a report from the European Association of Cardiovascular Imaging and the American Society of Echocardiography. Eur Heart J Cardiovasc Imaging 2013;14:721–40.

180. Zamorano JL, Lancellotti P, Rodriguez Munoz D, et al. 2016 ESC position paper on cancer treatments and cardiovascular toxicity developed under the auspices of the ESC Committee for Practice Guidelines: The Task Force for Cancer Treatments and Cardiovascular Toxicity of the European Society of Cardiology (ESC). Eur J Heart Fail 2017;19:9–42.

181. Saxena P, Joyce LD, Daly RC, et al. Cardiac transplantation for radiation-induced cardiomyopathy: the Mayo Clinic experience. Ann Thorac Surg 2014;98:2115–21.

182. Al-Kindi SG, Oliveira GH. Heart transplantation outcomes in radiation-induced restrictive cardiomyopathy. J Card Fail 2016;22:475–8.

KEY WORDS heart failure, restrictive cardiomyopathy, sarcoidosis