JOURNAL OF THE AMERICAN COLLEGE OF CARDIOLOGY
VOL. 71, NO. 10, 2018

PUBLISHED BY ELSEVIER

THE PRESENT AND FUTURE

STATE-OF-THE-ART REVIEWS

Spectrum of Restrictive and Infiltrative Cardiomyopathies

Part 1 of a 2-Part Series

Naveen L. Pereira, MD,[a] Martha Grogan, MD,[a] G. William Dec, MD[b]

ABSTRACT

Restrictive cardiomyopathies are the least common form of heart muscle disease. They are characterized as infiltrative and noninfiltrative, storage diseases, and endomyocardial disorders. Genetic diseases commonly present during childhood or adolescence. However, a growing percentage of elderly patients with heart failure with preserved ejection fraction are being recognized as having forms of restrictive cardiomyopathy, particularly cardiac amyloidosis. Noninvasive evaluation has replaced endomyocardial biopsy in the diagnostic evaluation of most suspected etiologies. The detection of infiltrative cardiomyopathies, including lysosomal and glycogen storage disorders, iron overload, and amyloidosis (both light chain amyloidosis and transthyretin amyloidosis variants), as well as inflammatory diseases such as sarcoidosis has slowly led to improved outcomes via disease-specific therapies. (J Am Coll Cardiol 2018;71:1130–48) © 2018 by the American College of Cardiology Foundation.

Cardiomyopathies are primary diseases of the heart muscle that may arise from a variety of underlying conditions including genetic abnormalities, myocyte injury, or infiltrative processes of the myocardial and interstitial tissues. The 3 principal classifications based on their phenotype are dilated, hypertrophic, and restrictive cardiomyopathies (RCMs) (1,2). Processes that lead to abnormal deposition of proteins within the myocardium lead to increased ventricular stiffness, the prototypical example being amyloidosis. The RCMs are the least frequently encountered form of primary heart muscle disease in adults within the developed world (2,3). RCMs should be classified according to their etiology as either primary or secondary. Hypertensive heart disease and hypertrophic cardiomyopathy (HCM) must be excluded, as depicted in the **Central Illustration**. Primary RCM includes idiopathic RCM and endomyocardial fibrosis. Common secondary forms include infiltrative cardiomyopathies, particularly amyloidosis as well as sarcoidosis; primary and secondary forms of hemochromatosis; storage disorders such as Fabry disease; and metastatic cancer and radiation-induced forms of disease. A clinically useful classification system is shown in **Table 1**.

RCM in younger adults (<30 years of age) is largely due to genetic abnormalities that lead to increased fibrosis, abnormal deposition of iron, proteins, or glycogen. Conversely, RCM in older adults (>65 years of age) is confined to a smaller number of distinct etiologies. Idiopathic RCM is rare, but may occur in patients in this age group. More common causes are cardiac amyloidosis, iron overload conditions, and radiation-induced heart disease. Sarcoidosis may also occur but is distinctly uncommon in this age group. Each condition will be discussed separately in greater detail.

Listen to this manuscript's audio summary by *JACC* Editor-in-Chief Dr. Valentin Fuster.

From the [a]Department of Cardiovascular Diseases, Mayo Clinic, Rochester, Minnesota; and the [b]Cardiology Division, Massachusetts General Hospital, Boston, Massachusetts. Dr. Pereira is funded in part by the National Institute on Aging grant R21AG53512. Dr. Grogan has received consulting fees from Alnylam, Pfizer, and Prothena; and has received research support from Alnylam and Pfizer. Dr. Dec has reported that he has no relationships relevant to the contents of this paper to disclose. Robert James Siegel, MD, served as Guest Editor for this paper.

Manuscript received October 5, 2017; revised manuscript received January 10, 2018, accepted January 10, 2018.

ISSN 0735-1097/$36.00
https://doi.org/10.1016/j.jacc.2018.01.016

RCMs have distinct morphological and hemodynamic characteristics. Wall thickness is generally normal but may be increased with infiltrative processes. Systolic function measured by ejection fraction is typically normal until advanced stages of disease ensue. The ventricular myocardium has increased stiffness that results in severe diastolic dysfunction, restrictive filling pattern with elevated filling pressures, normal left ventricular (LV) cavity size and dilated atria. The noncompliant left ventricle demonstrates rapid elevation in filling pressures with only small increases in volume. Most conditions affect both the right and left ventricles and may cause signs and symptoms of right, left, or biventricular failure.

Although pathophysiological features of RCM are similar to other forms of diastolic dysfunction, including heart failure with preserved ejection fraction (HFpEF), the traditional criteria applicable to making a diagnosis of RCM, such as normal LV chamber size and wall thickness with dilated atria, are generally not used to diagnose HFpEF. Ventricular filling pressures are elevated at rest and rise rapidly during exercise due to ventricular noncompliance. The noncompliant left ventricle inhibits rapid venous return and results in limited increases in stroke volume. Progressive atrial enlargement can lead to atrial arrhythmias and the development of secondary atrioventricular regurgitation. Thromboembolic complications, with or without concomitant atrial fibrillation, are not uncommon due to marked biatrial enlargement and poor atrial contractility. Renal dysfunction commonly ensues as the disease progresses, likely due to elevated systemic filling pressures and reduced stroke volume.

CLINICAL CHARACTERISTICS

Heart failure is the most common initial manifestation, with dyspnea on exertion a typical feature. Exercise intolerance is frequently present due to the inability of the ventricle to fill adequately at higher heart rates. Fatigue and lower extremity edema are also prominent features. Chest pain may occur, but is infrequent. Physical examination typically reveals prominent right-sided findings including jugular venous distention and prominent x and y descents without respiratory variation (negative Kussmaul's sign). The apical impulse may be mildly displaced but is usually palpable. S_1 and S_2 are normal; there is typically a loud S_4 gallop, and an S_3 gallop is not infrequently audible. Hepatomegaly, ascites, and marked pedal edema may occur as the disease progresses. Mitral and tricuspid regurgitation are frequently present.

The chest film usually shows a normally sized ventricular silhouette with enlarged atria and varying degrees of pulmonary congestion. Electrocardiogram (ECG) exhibits sinus rhythm with large P waves indicative of biatrial enlargement accompanied by nonspecific repolarization abnormalities. Atrial fibrillation, however, is not uncommon. Low voltage, a pseudoinfarction pattern, bundle branch block, and AV block should suggest an infiltrative process or sarcoidosis.

ABBREVIATIONS AND ACRONYMS

AL = light chain amyloidosis

ATTR = transthyretin amyloidosis

CMR = cardiac magnetic resonance imaging

HFpEF = heart failure with preserved ejection fraction

PYP = pyrophosphate

RCM = restrictive cardiomyopathy

DIAGNOSTIC EVALUATION

ECHOCARDIOGRAPHY. Transthoracic echocardiography is a critical initial step in diagnosing HFpEF (**Central Illustration**) that includes diseases such as restrictive and infiltrative cardiomyopathies. Echocardiography in RCM typically demonstrates normal right and LV ejection fraction, normal chamber volumes with biatrial enlargement, and restrictive diastolic filling parameters. Increased LV wall thickness after excluding causes such as hypertensive heart disease and HCM is seen with infiltrative processes. Abnormal diastolic compliance is characterized by the following Doppler echocardiographic findings: increased early diastolic filling velocity (E waves) reflecting elevated left atrial pressure, decreased atrial filling velocity (A-wave) due to elevated ventricular diastolic pressures, E/A ratios >1.5, decreased mitral deceleration time (DT <120 ms), and decreased isovolumetric relaxation time (**Figure 1**) (4). A markedly decreased systolic/diastolic pulmonary venous flow ratio is typically seen due to high atrial filling pressures and augmented atrial reversal velocity consequent to decreased ventricular compliance (4). Doppler tissue imaging (DTI) reveals reduced early diastolic longitudinal axis or mitral annular velocities (e′), a measurement that is relatively independent of pre-load and an increased E/e′ ratio (5).

CARDIAC MAGNETIC RESONANCE IMAGING. Cardiac magnetic resonance imaging (CMR) is a powerful diagnostic tool for assessing patients with suspected pericardial or myocardial disease. RCM on CMR typically appears as normal-volume ventricles with marked atrial enlargement (6). Although myocardial wall thickness that is frequently increased in RCM due to infiltrative processes and ventricular volumes are accurately measured in cine steady-state free precession sequences, the value of CMR lies in its

CENTRAL ILLUSTRATION Diagnostic Approach to Various Causes of Restrictive Cardiomyopathy When Patients Present With Heart Failure With Preserved Ejection Fraction

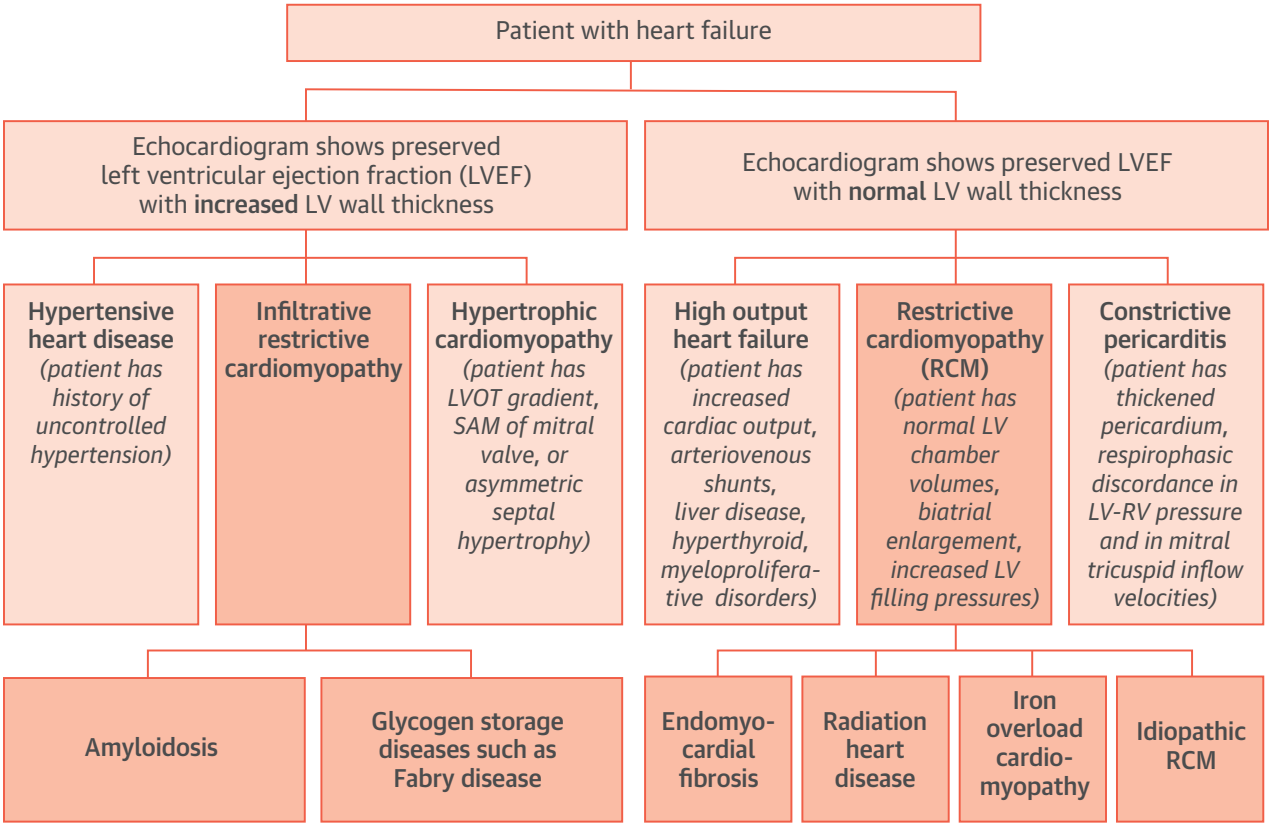

Pereira, N.L. et al. J Am Coll Cardiol. 2018;71(10):1130–48.

LV = left ventricular; LVEF = left ventricular ejection fraction; LVOT = left ventricular outflow tract; RCM = restrictive cardiomyopathy; RV = right ventricular; SAM = systolic anterior motion.

ability to accurately characterize myocardial tissue based upon the intrinsic magnetic properties of different tissues and the distribution patterns of gadolinium-based contrast agents. Fast spin-echo T_2-weighted sequences or quantitative T_2 mapping may indicate myocardial edema and inflammation that appear as hyperintense areas, and in contrast, decreased T_2-weighted signal intensities are seen in iron overload myocardial disorders (7). Delayed myocardial enhancement, indicative of myocardial inflammation or fibrosis, is seen in approximately one-third of all cases of RCM (8). Contrast-enhanced T_1 mapping is useful in quantifying diffuse myocardial fibrosis (9). Delayed enhanced inversion recovery imaging that results in nulling of normal myocardium and other cine-imaging characteristics can help identify specific infiltrative cardiomyopathies, such as amyloid, that result in restrictive myocardial disease (10). Delayed gadolinium enhancement often provides incremental prognostic information beyond serum biomarkers, such as immunoglobulin light chains in cardiac AL amyloidosis (11). T_1 may prove to be more sensitive than gadolinium for detecting early amyloid deposits.

CARDIAC CATHETERIZATION. Hemodynamic findings include elevation of right- and left-sided filling pressures with reduction in cardiac index. Right atrial pressure is elevated with prominent x and y descents. The classic square root sign (i.e., a prominent early decrease in ventricular diastolic pressure followed by a rapid rise to a plateau phase) characterizes restrictive physiology (**Figure 2**). Right ventricular

systolic pressure is often >50 mm Hg, while right ventricular diastolic pressures are usually less than one-third of systolic pressure. LV diastolic pressure is typically ≥5 mm Hg higher than right ventricular end-diastolic pressure; however, it is not uncommon for both pressures to be nearly identical (12). This difference may be accentuated by the Valsalva maneuver, exercise, or an acute fluid challenge. Finally, unlike constrictive pericarditis, there is no discordance of intracavitary and intrathoracic pressures (**Figure 2**) (12).

ENDOMYOCARDIAL BIOPSY. Unlike dilated and hypertrophic cardiomyopathies, endomyocardial biopsy plays an important role in the diagnostic evaluation of patients with restrictive disease (American Heart Association [AHA]/American College of Cardiology [ACC] Class IIa recommendation) (13). Cardiac involvement in systemic diseases such as amyloidosis and hemochromatosis can be definitively established by right ventricular biopsy. Biopsy is occasionally useful in differentiating restrictive disease from constrictive pericarditis (14). Although CMR (particularly T_1, T_2, and extracellular volume mapping) has increasingly diminished the need of performing an endomyocardial biopsy from a diagnostic perspective, a tissue diagnosis is sometimes needed to identify forms of RCM with targeted therapies (i.e., sarcoidosis, amyloidosis, and Fabry disease). However, a recent series from Johns Hopkins noted that right ventricular biopsy was diagnostic in only 29% of patients with heart failure with unexplained RCM (14).

TABLE 1 Etiologies of Restrictive Cardiomyopathy in Adults

Myocardial Process	Children/Adults (Age <30 Years)	Adults (Age 30–65 Years)	Older Adults (Age >65 Years)
Noninfiltrative			
	Idiopathic RCM	Idiopathic RCM	Idiopathic RCM
	Scleroderma	Scleroderma	
		Pseudoxanthoma elasticum	
Infiltrative			
		Amyloidosis	Amyloidosis
	Sarcoidosis	Sarcoidosis	
	Gaucher's		
	Hurler's		
Storage diseases			
	Fabry's disease		
	Glycogen storage		
	Hemochromatosis		
		Iron overload	Iron overload
Endomyocardial			
	Endomyocardial fibrosis		
	HES	HES	HES
		Carcinoid	
			Metastatic tumor
			Radiation-induced
		Drugs*	Drugs*

*Drugs: anthracyclines, ergotamine, chloroquine.
HES = hypereosinophilic syndromes; RCM = restrictive cardiomyopathy.

CONSTRICTIVE PERICARDITIS VERSUS RCM

Constrictive pericarditis is a late sequela of chronic pericarditis. It is increasingly seen in patients following cardiac surgery and those who have received chest irradiation for treatment of a malignancy. Although the clinical manifestations and physical findings of constrictive pericarditis and RCM are similar, their pathophysiological and hemodynamic abnormalities differ significantly. Marked reduction in LV chamber compliance is a hallmark of both conditions. In RCM, reduced compliance is caused by abnormal properties of the myocardium and/or interstitial matrix, whereas in constrictive pericarditis, it is imposed by external constraint. Myocardial relaxation is impaired in RCM, but is typically normal in constrictive disease (5,15). Patients with constrictive pericarditis exhibit exaggerated interventricular dependence and dissociation between intracardiac and intrathoracic pressures during respiration (**Figure 2**) (5,15). Echocardiography, CMR, and/or invasive hemodynamic measurements can assess the fundamental changes and differentiate the 2 conditions. Echocardiography is the initial imaging test of choice. Echocardiography may detect the presence of a thickened (>4 mm) pericardium, but is less useful then computed tomography or CMR imaging (12).

Systemic venous congestion is present in both conditions. A plethoric inferior vena cava and engorged hepatic veins are typically seen in RCM and constriction. Absence of inferior vena cava dilation in a patient without recent diuresis should call into question the diagnosis of hemodynamically significant constrictive pericarditis or RCM (12).

The most specific sign on echocardiography of constrictive pericarditis is shifting of the septum during the respiratory cycle, caused by the variability in venous return in exaggerated interventricular dependence (5,12,15–17). Detailed Doppler evaluation is essential to the diagnosis of both constrictive pericarditis and RCM, and in many cases, can confirm constrictive physiology without the need for invasive hemodynamic assessment. Mitral and tricuspid Doppler inflow signals in both conditions demonstrate early diastolic velocity (E-wave) predominance with a short deceleration time, reflecting the predominance of early rapid ventricular filling.

JACC VOL. 71, NO. 10, 2018
MARCH 13, 2018:1130–48

FIGURE 1 Echocardiographic Findings in Restrictive Cardiomyopathy

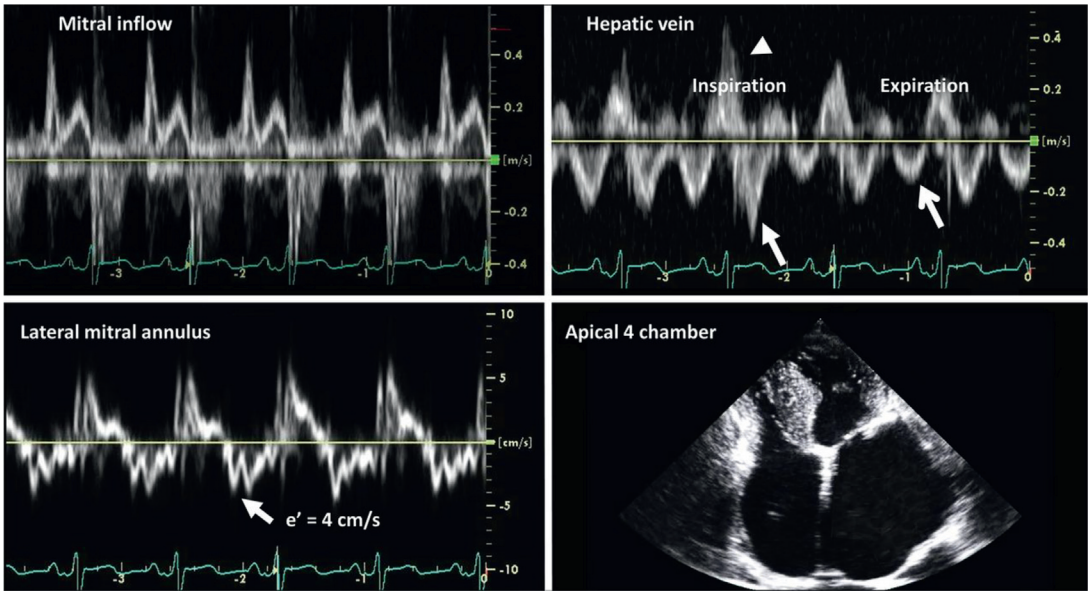

(Upper left panel) Pulsed-wave Doppler of the mitral inflow, which demonstrates a restrictive pattern, with early diastolic mitral inflow Doppler velocity (E) greater than late velocity (A) and short deceleration time. **(Upper right panel)** Hepatic vein pulsed-wave Doppler showing increased inspiratory forward velocities **(arrow)**, inspiratory diastolic flow reversals **(arrowhead)**, and minimal expiratory diastolic flow reversals **(rounded arrow)**. **(Lower left panel)** Lateral mitral annulus tissue Doppler demonstrating markedly reduced early diastolic velocity (e′). **(Lower right panel)** Apical 4-chamber 2-dimensional echocardiogram revealing marked biatrial enlargement. Reprinted with permission from Geske et al. (12).

Respiratory flow variation is absent in RCM (**Figure 1**) but is frequently noted in constrictive pericarditis (17,18). Initial reports described mitral inflow in constrictive pericarditis as demonstrating respiratory variation >25% with increased velocities during expiration (18). However, more recent studies have shown that respiratory variation may be absent in up to one-third of patients with constrictive pericarditis (19). Tricuspid inflow Doppler demonstrates the reverse finding, namely a >40% increase in tricuspid velocity in the first beat after inspiration in constrictive pericarditis (12). Atrial fibrillation results in variable cardiac cycle lengths and alterations in mitral inflow velocity. Although the abnormal rhythm makes evaluation for constrictive disease via mitral inflow Doppler signals challenging, hepatic vein flow reversal and annular tissue Doppler assessment remain reliable metrics (20).

Of all echocardiographic parameters, the most useful to distinguish the 2 conditions is tissue Doppler imaging (12). A normal tissue Doppler e′ velocity (>8 cm/s) indicates normal LV relaxation and virtually excludes RCM (5,15). Unlike normal patients, those with constriction demonstrate septal > lateral wall e′, which is partially due to limitation of lateral cardiac motion by pericardial constraint; hence, ventricular filling is more dependent on longitudinal cardiac motion (21). Consequently, mitral annular tissue Doppler e′ velocities are normal or paradoxically increased despite increased filling pressures, a finding termed *annular paradoxus* (22). A combination of echocardiographic characteristics provides better sensitivity and specificity than any single finding alone (**Table 2**) (20).

Novel echocardiography techniques, including 3-dimensional echocardiography and speckle tracking, are increasingly utilized to better define both constrictive disease and RCM (23). Myocardial deformation (LV strain) appears to be particularly promising, as preliminary studies suggest that patients with constrictive pericarditis have markedly abnormal circumferential deformation torsion and untwisting velocity but relative sparing of longitudinal mechanics, whereas RCM patients demonstrate abnormal longitudinal mechanics most pronounced at the base with relative sparing of LV rotation (24).

FIGURE 2 Simultaneous RV and LV Hemodynamic Assessment in Constrictive Pericarditis and Restrictive Cardiomyopathy

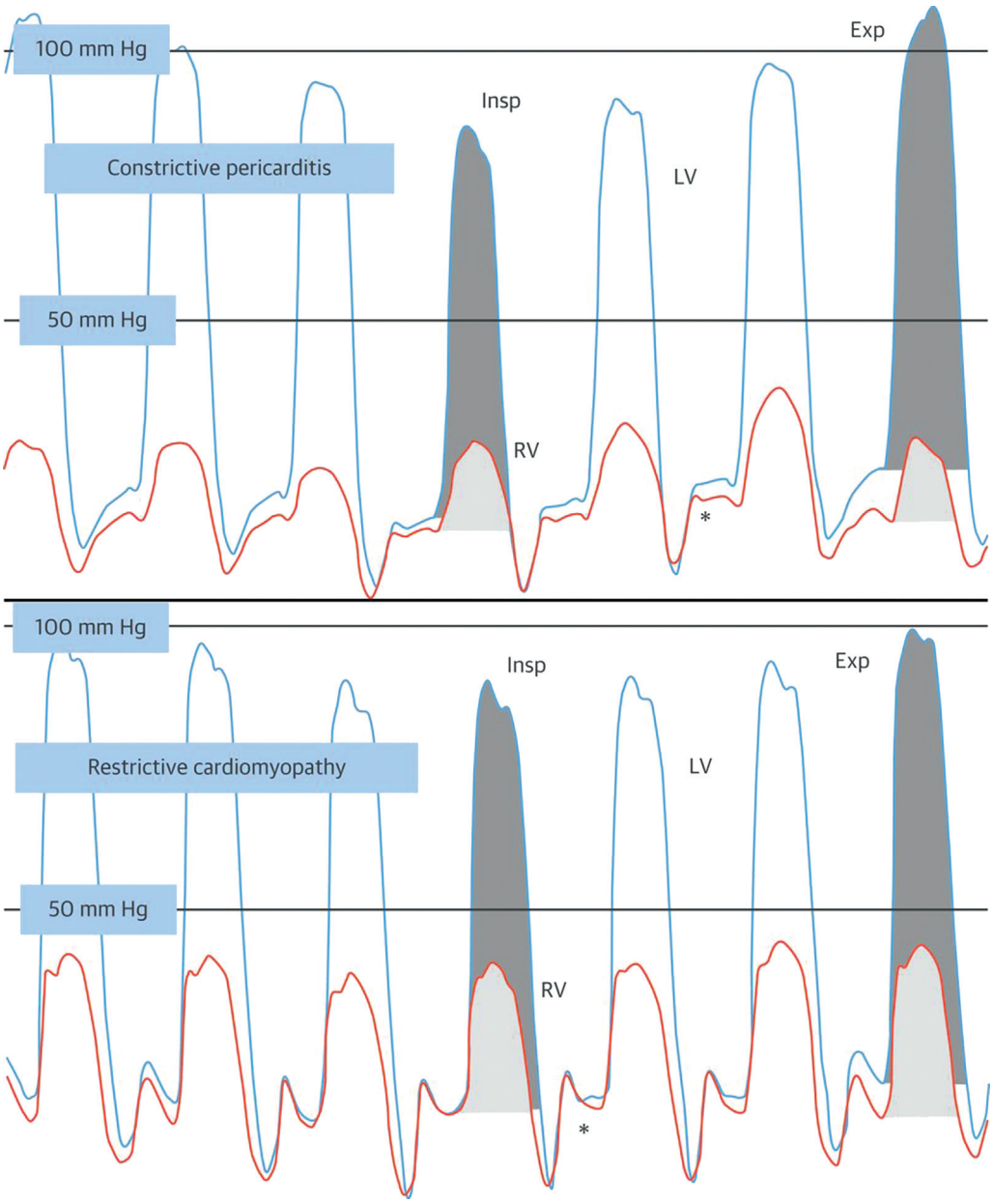

(Top) Left ventricular (LV) **(blue)** and right ventricular (RV) **(orange)** hemodynamic pressure tracings in constrictive pericarditis. End-diastolic filling pressures are elevated, and a "square root" sign is present on both tracings **(*)**. Enhanced ventricular interdependence is present, demonstrated by visualization of the systolic area index, RV **(light gray)** and LV **(dark gray)** areas under the curve for both inspiration (Insp) and expiration (Exp). During inspiration, there is an increase in the area of the RV pressure curve and a decrease in the area of the LV pressure curve. **(Bottom)** LV and RV pressure tracings in restrictive cardiomyopathy. End-diastolic pressures are elevated and a square root sign **(*)** is seen; there is no evidence of enhanced ventricular interdependence, with parallel changes in LV and RV pressure curve areas. Reprinted with permission from Geske et al. (12).

CMR has excellent accuracy (93%) for detecting pericardial thickening >4 mm (25). Tagged cine CMR can be useful in detecting tissue tethering or lack of slippage (26,27). Adherence of the visceral and parietal pericardium can result in persistent discordance of tagged signals between tissue planes throughout systole and diastole and is quite effective in diagnosing constrictive pericarditis.

JACC VOL. 71, NO. 10, 2018
MARCH 13, 2018:1130–48

TABLE 2 Echocardiographic Characteristics of Confirmed Constrictive Pericarditis

	Sensitivity	Specificity	PPV	NPV
1. Ventricular septal shift	93	69	92	74
2. Change in mitral E velocity >14.6%	84	73	92	55
3. Medial e′ velocity >9 cm/s	83	81	94	57
4. Medial e′/lateral′ ≥0.91	75	85	95	50
5. Hepatic vein diastolic reversal velocity/forward velocity in expiration ≥0.79	76	88	96	49
1 and 3	80	92	97	56
1 with 3 or 5	87	91	97	65
1 with 3 and 5	64	97	99	42

Values are %. Reprinted with permission from Welch et al. (20).

E = early diastolic mitral inflow Doppler velocity; e′ = early diastolic mitral annular tissue Doppler velocity; NPV = negative predictive value; PPV = positive predictive value.

GENERAL TREATMENT PRINCIPLES

Conventional treatment should be aimed at relieving congestive symptoms. Judicious use of loop diuretics is essential to control pulmonary congestion, peripheral edema, and ascites. However, even mild hypovolemia due to overdiuresis in the presence of a nondilated, nondistensible ventricle can lead to further decline in stroke volume and cause hypotension, worsening prerenal azotemia, and low-output state. A 2- to 4-g sodium restriction and 2-l fluid restriction should be recommended. Supraventricular arrhythmias, particularly atrial fibrillation, occur commonly and are poorly tolerated. Rhythm control with the use of antiarrhythmic agents rather than rate control may contribute to normal atrial contractility and improve diastolic filling to preserve stroke volume. Bradyarrhythmias, although uncommon in restrictive or infiltrative heart disease, may require permanent AV sequential pacer implantation. No pharmacological treatment has been shown to specifically improve diastolic filling or to prolong survival except heart transplantation in eligible patients. Therapy should be directed toward the specific underlying disease etiologies when identified.

GENETICS OF RCM

Prior to the identification of specific disease-causing mutations, a genetic etiology for RCM was strongly suspected based upon familial occurrences. A key observation was the coexistence of an RCM phenotype with mutations in the HCM-associated genes. From >1,200 patients with familial HCM, 1.5% had phenotypes diagnostic of RCM (28). One-half of the RCM probands had pathologic mutations identified in either beta-myosin heavy chain (*MYH7*) or the cardiac troponin I gene (*TNNI3*) (28). All RCM patients with an identified mutation demonstrated either marked myofibrillar disarray on biopsy, thus demonstrating a mixed phenotype with HCM, or had relatives with an unequivocal diagnosis of HCM (28). The restrictive phenotype was associated with more dyspnea, lower exercise capacity, and a higher composite rate (56%) of mortality, cardiac transplant, or implantable cardioverter-defibrillator (ICD) discharges (28). The limitation of this study is that genetic analysis for recognized HCM-causing genes was performed, and whether other genetic modifiers were present that resulted in the RCM phenotype is unknown. Mogensen et al. (29,30) used linkage analysis followed by direct sequencing to identify a 87A-G nucleotide substitution on exon 8 of *TNNI3*, which was associated with marked restrictive physiology and a history of sudden cardiac death. It now appears that mutations in *TNNI3* are responsible for the development of RCM in a significant percentage of young patients diagnosed with disorder (29). The majority of mutations in *TNNI3* are generally missense; rarely, frame shift or splice mutations have been reported (30). Troponin I mutation phenotypes typically do not show significant loss of protein expression, but they demonstrate marked myofibrillar disarray even in the absence of significant LV hypertrophy. A mutational analysis of 9 unrelated HCM patients with an extreme restrictive filling pattern, marked atrial dilation, and normal wall thickness was recently reported (31). Myocardial histology demonstrated the typical myofibrillar disarray characteristic of HCM. *TTNI3* mutations were identified in the majority of these patients (31).

Mutations in other sarcomeric genes including troponin T (*TTNT2*), myosin-binding protein C (*MYBPC3*), myosin light chains (*MYL 2* and *3*), and alpha cardiac actin (*ACTC*) have also been described (32,33). Menon et al. (34) have reported a mutation in *TTNT2* that is inherited in an autosomal dominant manner and may present with 3 distinct clinical phenotypes: RCM, HCM, or DCM. Linkage analysis followed by sequencing identified a missense mutation resulting in I79N substitution in *TTNT2*. The identified sarcomeric mutations appear to occur de novo with severe disease expression in childhood, leading to premature death or heart transplantation (35).

Nonsarcomeric mutations have also been recently identified in RCM. Mutations in myopalladin (*MYPN*) and titin (*TTN*) may cause myofibrillar disarray and restrictive physiology (36). The mechanism proposed for development of RCM is altered myofibrillogenesis.

Mutations in filament-C (FLNC) have also been identified in several families and demonstrate autosomal dominant inheritance. FLNC is an actin cross-linking protein expressed in the heart and skeletal muscle. Cardiac myocytes show cytoplasmic inclusions suggesting protein aggregates which were specific for filament-C by immunohistochemistry (37).

Several mutations associated with clinical RCM have been studied in murine models. Mutant animals carrying the *TTNI3 R193H* missense mutation that was associated with the human restrictive phenotype in HCM developed early diastolic dysfunction, small chamber size, and reduced LV function (38). Mice with cardiac-targeted expression of the *TTNT2 I79N* mutation show enhanced calcium-activated force generation and adenosine triphosphate activity, reduction in calcium dissociation from troponin C, slowed myocardial relaxation, and elevation in end-diastolic pressure (38). The mice did not demonstrate cardiac hypertrophy, but developed an RCM phenotype. A MYPN mutation in myopalladin has also been shown to produce increased cardiac fibrosis, reduced LV chamber size, and diastolic dysfunction in an animal model of RCM (39).

The desmin intermediate filament network is essential in striated muscle for coordinating cellular components that are necessary for intracellular mechanical chemical signaling and trafficking processes (40). Desmin-related RCMs are very rare disorders, characterized by intracytoplasmic accumulation of desmin and caused by mutations in the gene for desmin (DES) or alpha-beta crystallin (CRYAB) (41,42). Disease expression is variable and may involve skeletal muscle alone, cardiac and skeletal muscle simultaneously, or cardiac muscle alone (43). Conduction disease is typically present, and has been confirmed in animal models; it should be considered in young patients with RCM and atrioventricular block (41,43).

The coexistence of HCM and RCM phenotypes within the same families, and consequent to identical disease-causing mutations, highlights the importance of modifier genes, epigenetics, and environmental influences in determining the ultimate clinical phenotype (35). Hereditary forms of RCM may not typically be a distinct genetic cardiomyopathy; rather, they may represent part of the broad phenotypic spectrum of HCM that is manifested by limited (or absent) hypertrophy and restrictive physiology (44). Finally, clinicians must be mindful that not all forms of familial RCM have an identified genetic basis, and not all RCM patients with an identified mutation will have an affected family member due to variable penetrance.

APPLICATION OF THE MOGES CLASSIFICATION TO RCM

Due to the heterogeneity in both phenotype and genotype, a new classification system for accurately describing the various cardiomyopathies was adopted in 2013 by the World Heart Federation (45). This new system addresses 5 attributes that are common to all cardiomyopathies: morphological functional characteristics (M), organ involvement (O), genetic or familial inheritance pattern (if known) (G), an explicit etiological category (E) with details of genetic defect or underlying disease/cause, and information on functional status (S) using the American College of Cardiology/American Heart Association Stages (A to D) and the New York Heart Association (NYHA) functional class (I to IV). This nosologic criteria defines a novel descriptive classification that combines morphology, organ system involvement with familial inheritance pattern, and identified genetic defects or other etiologies.

This new classification is readily applicable to specific forms of RCM. For desmin-related RCM: $M_{R(AVB]}$ O_{H+M} G_{AD} $E_{G\text{-}Des[p.Gly84\ Ser]}$ $S_{C\text{-}III}$ represents morphofunctional phenotype (M): RCM with AV block; organ (O) involvement: heart (H) and skeletal muscle (M); genetic/familial (G) with autosomal dominant transmission (AD); etiology (E): genetic (G) caused by the p.Gly84Serine mutation in the desmin gene; ACC/AHA stage (S) C, NYHA functional class III.

For light chain amyloidosis: $M_{R\ (low\ ECG\ voltage)}$ O_{H+K} G_N $E_{A\text{-}L}$, $S_{B\text{-}II}$ represents morphofunctional phenotype RCM (R) with low voltage on ECG; organ (O) involvement: heart (H) and kidney (K); genetics/familial (G): negative family history (N); etiology (E): amyloidosis (A), amyloidogenic light chain lambda (L); ACC/AHA stage B, NYHA functional class II.

IDIOPATHIC RCM

Primary (idiopathic) RCM is a rare disease that may present at any age (3). Increased myofilament sensitivity to calcium, increased deposition of collagen type III, and marked deposition of desmin have all been implicated in the pathogenesis of this condition (5,46,47). Familial disease as well as sporadic cases has been described (3,35). Autosomal dominant inheritance with variable penetrance characterizes familial cases. Skeletal myopathy, particularly affecting distal muscles of the extremities, as well as atrioventricular block are present in some familial cases (48).

Considerable overlap exists between restrictive RCM and HCM with minimal LV hypertrophy. Further,

RCM, particularly in older adults, may be difficult to differentiate from constrictive pericarditis. Several small series have recorded that mean plasma B-type natriuretic peptide (BNP) is considerably higher in patients with RCM than those with constrictive pericarditis (e.g., 825 pg/ml vs. 120 pg/ml) (49). However, considerable overlap exists between groups, particularly for BNP levels <400 pg/ml or when renal dysfunction is present (50).

In the largest reported series by Ammash et al. (51), 94 patients were identified with a mean age of 64 years at diagnosis (range 10 to 90 years). Importantly, there were >15% of patients who presented at age >80 years. None had known infiltrative disease, long-standing untreated hypertension, or cardiac or systemic conditions known to impair diastolic ventricular filling. Atrial fibrillation was present in 74% of patients. Endomyocardial biopsy demonstrated diffuse fibrosis and myocyte hypertrophy. Actuarial survival free of heart transplantation at 5 years was 64%, compared with an expected survival of 85% for age-matched control subjects. Multivariate analysis demonstrated the risk of death doubled for males, left atrial dimension >60 mm, age >70 years, and higher NYHA functional class (51). Prognosis is also substantially worse among children with this disorder (3). Treatment is largely supportive with judicious use of loop diuretic agents to control volume retention and systemic anticoagulation for atrial fibrillation as the incidence of thromboembolic complications is increased. Heart transplantation is an effective therapy for patients with end-stage disease, but is often precluded by the presence of coexisting pulmonary hypertension (52). In select centers, modified-approach LV assist device therapy has improved hemodynamics and has been used successfully to transition these patients to heart transplantation (53).

INFILTRATIVE CARDIOMYOPATHIES: LYSOSOMAL STORAGE DISEASES

Of the 40 storage disorders caused by deficient enzymatic activity of lysosomal enzymes, Anderson-Fabry disease, Danon disease (lysosomal-associated membrane protein-2 [LAMP2]), and protein kinase AMP-activated noncatalytic subunit gamma 2 (PRKAG2)-deficient cardiomyopathy are the principal diseases associated with cardiac involvement (5,54,55).

Anderson-Fabry disease is the most common glycogen storage disorder, affecting approximately 1 in 50,000 individuals (55). It is an X-linked recessive disorder due to reduced or absent activity of alpha-galactosidase A caused by mutations in the *GLA* gene. This deficiency results in progressive accumulation of globotriaosylceramide in the heart, kidneys, and nerves. The disease generally presents during childhood or early adulthood, with varying degrees of unexplained LVH. Painful extremities related to peripheral neuropathy and cutaneous lesions often dominate the initial presentation. The skin lesions (angiokeratoma corporis diffusum) are characteristic and demonstrate elevated papules that occur in the midsection, buttocks, and upper thighs (55). Many patients eventually develop chest pain, dyspnea, and palpitations (56).

Cardiac manifestations often present in the third decade in males and later in heterozygous females (56). An atypical disease variant occasionally is encountered with unexplained LV hypertrophy in adults in their sixth to eighth decade who lack the more commonly encountered findings in children and young adults, specifically acroparesthesias and skin lesions. ECG abnormalities include a short PR interval, right bundle branch block, LV hypertrophy, and giant negative T waves (57). This disorder is not associated with diminished QRS voltage, as the abnormal deposition occurs in the cardiomyocyte rather than the interstitium. LV wall thickness and mass increases as age and disease severity progress (55,57). Tissue Doppler echocardiography shows a decrease in systolic and diastolic myocardial velocities, even before the development of LVH (58). CMR often demonstrates midmyocardial late enhancement involving the basilar inferolateral wall with sparing of the subendomyocardium, or a more diffuse pattern in patients with severe LVH. Demonstration of decreased or absent serum or leukocyte alpha galactosidase A activity or sequencing the *GLA* gene for likely pathogenic or pathogenic variants is required to establish the diagnosis. Endomyocardial biopsy, which is occasionally necessary when genetic testing or alpha galactosidase A activity results are equivocal, reveals concentric lamellar bodies in the sarcoplasm of myocardial cells (**Figure 3**) (55,59).

Enzyme replacement therapy administered early has been shown to produce substantial clinical benefit. Replacement therapy with L-algalsidase-beta decreases LV wall mass; improves systolic and diastolic function; and reduces major adverse outcomes, including renal failure, stroke, cardiac events, and death (60-62). The U.S. Food and Drug Administration has recently granted orphan drug status to AT1001, a small molecule pharmacological chaperone that stabilizes L algalsidase-alpha and prevents its rapid denaturation and activity loss.

Danon disease, a glycogen storage disorder, is a rare X-linked dominant disease due to primary deficiency

FIGURE 3 Cardiac Histology in Fabry Disease

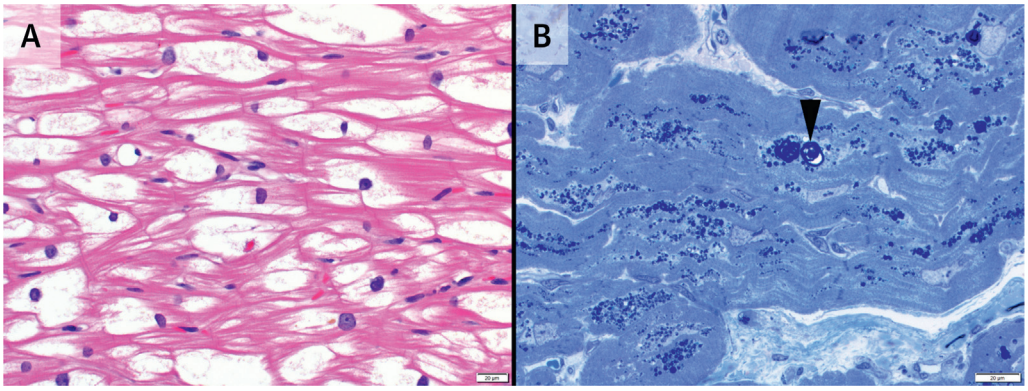

(A) Photomicrograph showing the extensive sarcoplasmic vacuolization on hematoxylin-eosin staining. **(B)** Ultrastructural studies reveal numerous sarcoplasmic myelin figures **(arrowhead)**. Reprinted with permission from Luis et al. (59).

of LAMP2 (54,55). Excess glycogen accumulates in cardiomyocytes and skeletal muscle fibers leading to formation of vacuoles that stain positive with periodic Acid Schiff (55). Typically affected adolescent males present with the triad of heart failure, predominantly an HCM phenotype, skeletal myopathy, and mental retardation. ECG findings demonstrate increased QRS voltage and deeply inverted T-wave abnormalities. Wolff-Parkinson-White syndrome occurs in both men and women (63). Echocardiographic features include LV hypertrophy (mimicking HCM) with extreme hypertrophy noted in some cases (maximal wall thickness >60 mm) (55,63). Skeletal muscle or cardiac biopsy demonstrating vacuolization, immunohistochemistry showing LAMP2 protein deficiency, and sequencing of the LAMP2 gene for mutations can be diagnostic. Clinical deterioration with rapidly progressive heart failure or sudden death before the age of 25 years is characteristic of the disease (63). Although there is no specific replacement therapy, catheter ablation can be effective in eliminating supraventricular tachycardia in patients with Wolff-Parkinson-White syndrome. Cardiac transplantation can also be considered in highly selected individuals (64).

PRKAG2 deficiency is a rare autosomal dominant disease with increased glycogen storage due to increased cellular uptake of glucose as opposed to a defect in glycogen degradation (55). Patients present at a young age with marked cardiac hypertrophy, skeletal myopathy, and arrhythmias often related to Wolff-Parkinson-White syndrome. LV systolic dysfunction and high-grade AV block necessitating pacemaker implantation may occur over time. Disease-specific therapy is currently lacking.

CARDIAC AMYLOIDOSIS

SCOPE OF THE PROBLEM. Cardiac amyloidosis is considered to be the prototype of the infiltrative form of RCM. Previously thought to be rare, it is now recognized that all forms of cardiac amyloidosis are likely underdiagnosed (65). Patients continue to present with end-stage cardiac disease, despite commonly seeing multiple providers over months to years before the correct diagnosis is established. Patient survey data demonstrates that although cardiologists are the most common subspecialists to whom amyloid patients are referred, the correct diagnosis is made in only approximately 20% of patients (66). The failure to establish the diagnosis of cardiac amyloidosis is multifactorial and is related to heterogeneity in presentation, failure to consider the diagnosis in a busy clinical setting, confusion about the types of amyloidosis, and the lack of knowledge of a proper diagnostic strategy. Recognition of cardiac amyloidosis is important for all cardiologists, as this is no longer a rare, untreatable disease.

TYPES OF AMYLOIDOSIS THAT COMMONLY AFFECT THE HEART. Amyloidosis is a disorder of misfolded proteins leading to deposition of insoluble amyloid fibrils in the heart and other tissues. Although cardiac amyloid types share common clinical manifestations and cardiac imaging findings, the diseases are very different in clinical presentation, diagnostic strategy, and prognosis, depending on the source and nature of

JACC VOL. 71, NO. 10, 2018
MARCH 13, 2018:1130–48

TABLE 3 Common Types of Amyloid With Cardiac Involvement

Type of Amyloid Pre-Cursor Protein (Source)	Clinical Features	PYP Scan Tissue Biopsy	Treatment
AL Immunoglobulin Light chain (bone marrow)	Heart failure Weight loss Nephrotic syndrome Peripheral/autonomic neuropathy	Negative or mild uptake Tissue biopsy mandatory	Chemotherapy Autologous stem cell transplant Monoclonal antibody
ATTR-m Transthyretin with mutation (liver)	Heart failure Peripheral/autonomic neuropathy	Positive* Diagnosis without tissue biopsy	Liver transplantation Diflunisal† Doxycycline and TUDCA‡ RNA-interfering therapy§
ATTR-wt Transthyretin without mutation (liver)	Heart failure Atrial fibrillation Conduction disease 90% male	Positive* Diagnosis without tissue biopsy‖	Diflunisal† Doxycycline‡ and TUDCA RNA-interfering therapy§

*Positive uptake defined as grade 2 (equal to) or 3 (greater than) bone; perform transthyretin DNA sequence to distinguish ATTR-m from ATTR-wt. †Caution with renal insufficiency, fluid overload, anticoagulant therapy, history of bleeding; monitor closely for worsening heart failure or renal failure. ‡Meticulous sun protection due to risk of photosensitivity, may require drug discontinuation. §Investigational. ‖If no evidence of plasma cell dyscrasia (normal serum and urine immunofixation and serum free light chain assay).

AL = light chain amyloidosis; ATTR-m = pathogenic transthyretin deoxyribonucleic acid mutation amyloidosis; ATTR-wt = wild-type transthyretin amyloidosis; DNA = deoxyribonucleic acid; PYP = pyrophosphate; RNA = ribonucleic acid; TUDCA = taurosodeoxycholic acid.

the precursor protein. Cardiologists often fail to understand these differences and consider cardiac amyloidosis to be "1 disease." Treatment depends *entirely* on the type of amyloid, and incorrect typing may lead to life-threatening mistakes in therapy.

There are 2 main types of amyloid that commonly affect the heart: immunoglobulin light chain associated amyloid (AL) (previously called "primary systemic amyloidosis") and transthyretin amyloid (ATTR). ATTR is further divided into a hereditary form due to a pathogenic transthyretin deoxyribonucleic acid (DNA) mutation (ATTR-m) and the "wild-type" (ATTR-wt), in which a mutation is not identified (**Table 3**). There are other rarer forms of cardiac amyloid that can be identified with use of a proper diagnostic strategy.

Current nomenclature uses "A" for amyloid followed by "X" to denote the precursor protein from which the fibrils are derived. Thus, immunoglobulin light chain amyloid is termed "AL" and transthyretin amyloid is "ATTR." This review will describe AL and ATTR separately in the following sections.

IMMUNOGLOBULIN LIGHT CHAIN AMYLOID

CLINICAL PRESENTATION. AL amyloid occurs due to a plasma cell dyscrasia with or without multiple myeloma, resulting in excessive immunoglobulin light chain production. There are approximately 3,000 new cases of AL per year in the United States (67). Patients generally present between ages 40 to 70 years with a slight male predominance. Although multiorgan involvement is common and may include the liver, kidneys, gastrointestinal tract, nervous system, and soft tissues, approximately 5% of patients have isolated cardiac involvement (68). The initial symptoms may be vague and nonspecific. Cardiac involvement is the primary determinant of outcome. However, cardiac amyloidosis is not a simple infiltrative cardiomyopathy. Direct toxicity of abnormal precursor proteins and other circulating factors contribute to myocardial dysfunction. Amyloidogenic light chains increase reactive oxygen species, which results in impaired myocardial contractility and relaxation in animal models (69). The direct "toxic" contribution of circulating free light chains to the pathophysiology that occurs in cardiac amyloidosis accounts for the discrepant findings of severe cardiac symptoms in some patients who have minimal or mild myocardial thickening (70).

Common presentations include heart failure, chest pain, and more commonly atrial but also ventricular arrhythmias. Stroke may occur due to cardiac embolus, as left atrial thrombi may develop even in sinus rhythm, presumably due to impaired atrial function due to amyloid infiltration (71,72). The combination of unexplained heart failure in association with hepatomegaly and or proteinuria should trigger consideration of the diagnosis of AL. Carpal tunnel syndrome may occur, but is less common in AL (<10%) than in ATTR (~35%) (73). Macroglossia and periorbital purpura are hallmarks of the diagnosis, but are relatively uncommon (<10%).

DIAGNOSIS. All patients with a suspicion of cardiac amyloidosis should have testing to determine the presence or absence of a plasma cell dyscrasia (**Figure 4**). Screening tests for AL include serum free light chains (kappa and lambda), and serum and or urine electrophoresis with immunofixation. The

FIGURE 4 Diagnostic Algorithm for Cardiac Amyloidosis

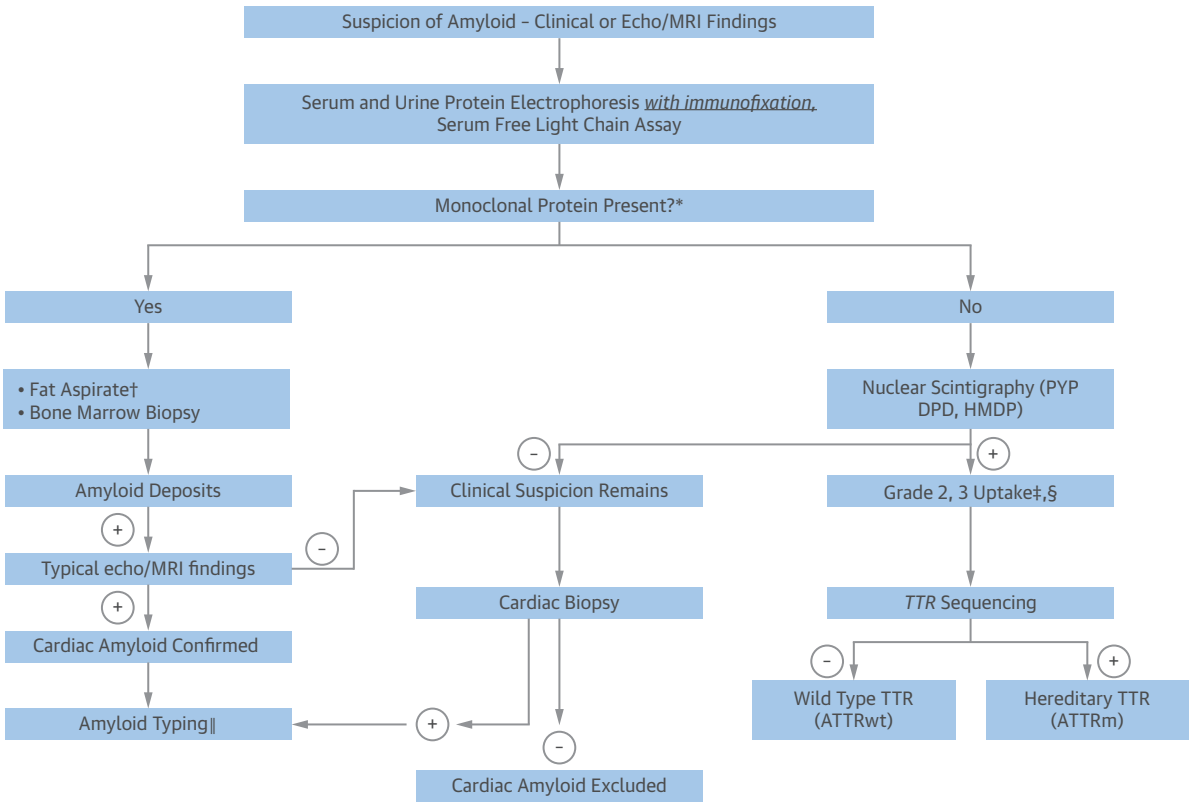

The diagnostic algorithm for cardiac amyloidosis includes cardiac or other tissue biopsy when suspicion of amyloid is present and other tests are negative, and the use of mass spectrometry for tissue typing will ensure that rare forms of amyloid are not missed. Reprinted with permission from Mayo Clinic. *Presence of monoclonal protein in serum/urine or abnormal free light chain ratio. †Fat aspirate if local expertise in acquisition and interpretation. Fat pad biopsy is an alternative. ‡Grade 2: moderate myocardial uptake (equal to bone); grade 3: severe uptake (greater than bone). §Rare amyloid types have been inadequately studied, may result in positive scans and can be confirmed by tissue amyloid typing. ‖Protein precursor identification with laser microdissection mass spectrometry. ATTR = transthyretin amyloidosis; ATTRm = pathogenic transthyretin deoxyribonucleic acid mutation amyloidosis; ATTRwt = wild-type transthyretin amyloidosis; DPD = 99mTc-labeled 3,3-diphosphono-1,2-propanodicarboxylic acid; Echo = echocardiography; HMDP = 99mTc-labeled hydroxymethylene-diphosphonate; MRI = magnetic resonance imaging; PYP = 99mTc-labeled pyrophosphate; TTR = transthyretin.

diagnosis of cardiac AL requires a positive tissue biopsy either from the heart or from a noncardiac site in those with typical cardiac imaging findings. The site of biopsy depends somewhat on local expertise. Fat aspirate and fat pad biopsy can be successfully used to diagnose amyloidosis, with positive findings in approximately 75% of patients (74). Bone marrow aspirate and biopsy establishes the nature of the clonal plasma cell disorder and increases the probability of obtaining tissue confirmation without cardiac biopsy. Cardiac biopsy is necessary in <15% of patients with AL (75), but should be performed if clinical suspicion remains and a diagnosis has not been unequivocally established. Endomyocardial biopsy is 100% sensitive for the detection of cardiac amyloidosis of any type (76).

Classic cardiac imaging findings of cardiac amyloidosis are instrumental in suggesting the diagnosis but are not definitive and do not reliably distinguish between types. Typical echocardiographic findings include left and right ventricular myocardial thickening, valvular thickening, pericardial effusion, diastolic dysfunction, and a characteristic pattern of global averaged longitudinal peak systolic strain with apical sparing (77) (**Figure 5**). CMR is helpful, particularly in patients who do not have characteristic echocardiographic findings. Characteristic CMR findings include: 1) abnormalities of late gadolinium enhancement, typically involving the subendocardium and atria; and 2) difficulty "nulling the myocardium" (78). T_1 imaging provides an assessment of extracellular volume, may suggest a

JACC VOL. 71, NO. 10, 2018
MARCH 13, 2018:1130–48

FIGURE 5 Imaging Studies in Cardiac Amyloidosis

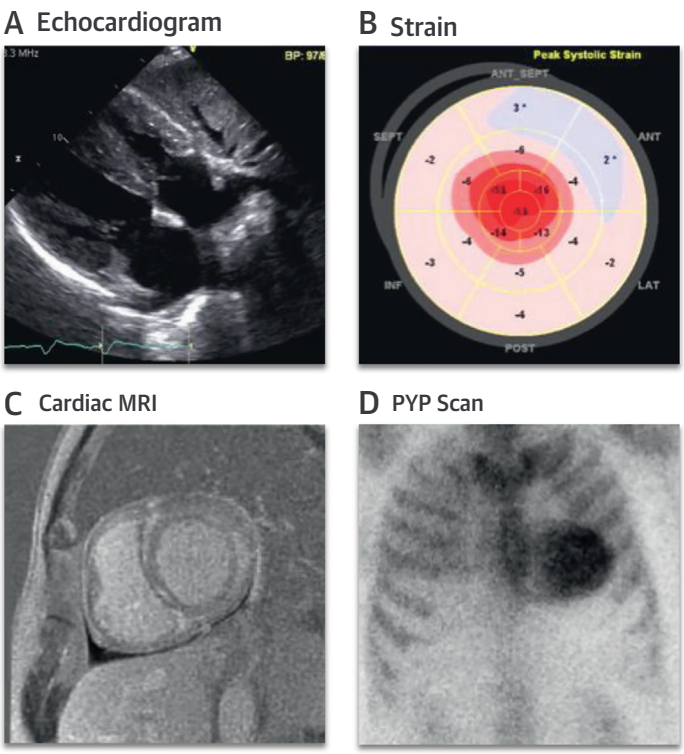

(A) Echocardiogram (subcostal view) demonstrating biventricular myocardial thickening and biatrial enlargement. **(B)** Strain imaging with markedly reduced global averaged peak longitudinal systolic strain with apical preservation ('bullseye") pattern, typical of cardiac amyloidosis. **(C)** Cardiac magnetic resonance imaging short-axis image with global subendocardial late gadolinium enhancement. **(D)** PYP scan shows severely increased myocardial uptake (grade 3, greater than bone) consistent with ATTR cardiac amyloidosis. Abbreviations as in Figure 4.

diagnosis in those patients with otherwise equivocal imaging, and is promising as a potential measure of response to therapy (79). The ECG in AL demonstrates low voltage and/or a pseudoinfarct pattern in 45% of patients. The absence of low voltage does not exclude the diagnosis, and ECG criteria for LV hypertrophy may be present in approximately 16% of patients (80). Correlation of the ECG with echocardiographic and CMR findings is important to suggest a diagnosis in those with myocardial thickening and an abnormal voltage to mass ratio (81).

A challenge in the diagnosis of AL is variation in the extent and distribution of amyloid. For example, amyloid may be primarily endocardial in distribution with little or no myocardial thickening. The concept of AL as a partly "toxic" rather than purely an "infiltrative" cardiomyopathy explains the discordant findings of some patients between symptoms and imaging (70). AL patients have been historically described as having preserved ejection fraction until late in the disease. However, patients may present with reduced LVEF even in the absence of myocardial thickening, likely due to the toxic effects of circulating free light chains and other substances (82). Recognition of the variability of imaging findings is important and can be the key to diagnosis in those without classic findings. AL amyloid can be diagnosed in 90% to 95% of patients with the combination of serum free light chains, serum and urine protein electrophoresis with immunofixation, and fat aspirate. If clinical suspicion remains high despite initial testing, endomyocardial biopsy should be pursued.

The presence of a monoclonal protein or an abnormal serum free light chain assay alone does not establish the diagnosis of AL amyloid, even in the presence of typical cardiac imaging findings. Monoclonal gammopathy of unknown significance (MGUS) is not uncommon, especially in those >65 years of age who may have cardiac ATTR and unrelated MGUS, and abnormal serum free light chain assays can also result due to renal insufficiency (83). Tissue typing of amyloid is crucial to establishing an accurate diagnosis and guiding therapy. Immunohistochemical techniques have been found to be inaccurate, and mistyping of amyloid can have life-threatening consequences, including patients with ATTR undergoing chemotherapy and autologous stem cell transplantation and those with AL receiving ineffective therapies. Laser microdissection mass spectrometry is the gold standard for determining amyloid type (76). Although available at limited centers, specimens can be sent to these centers for testing. An advantage of this technique is the ability to diagnose the less common types of amyloid that may affect the heart (serum amyloid A, apolipoprotein, gelsolin) by proteomic identification of the precursor protein. Mass spectrometry may suggest the presence or absence of a pathogenic transthyretin mutation; however, transthyretin DNA sequencing is required to establish the diagnosis of hereditary (ATTR-m) versus wild-type (ATTR-wt) amyloidosis. The diagnostic algorithm for cardiac amyloidosis is outlined in Figure 4; cardiac or other tissue biopsy when suspicion of amyloid is present and other tests are negative, and the use of mass spectrometry for tissue typing will ensure that rare forms of amyloid are not missed.

PROGNOSIS. Although overall survival for patients with AL is improving due to more effective treatment strategies, 12-month mortality remains high at approximately 24% in recent years (84). Patients with

more advanced cardiac disease have had worse survival, highlighting the need for earlier diagnosis. Of those who die within 6 months of diagnosis, one-half of those are due to sudden cardiac death. Although atrial and ventricular arrhythmias and conduction system disease are not infrequent in AL, many cases of sudden death are due to pulseless electrical activity (70). The high early mortality is likely due to delays in diagnosis, as patients with advanced disease do not live long enough to benefit from treatment. Overall survival in AL is determined by the extent of cardiac involvement, which can be assessed using cardiac biomarkers. The 2012 Mayo staging system incudes N-terminal BNP, troponin, and the difference in serum free light chains, and has been shown to be useful in predicting 2-year survival rates (85). Cardiac MR T_1 mapping has also been shown to be a strong predictor of prognosis. Banypersad et al. (86) demonstrated that increased extracellular volume (>45%) was associated with a hazard ratio for death of 3.84; prognostic significance persisted even when more traditional prognostic factors (e.g., elevated N-terminal pro-BNP and grade of diastolic dysfunction) were evaluated in multivariable analysis. Two-year overall survival has improved from 42% in patients diagnosed from 2000 to 2004 to 60% in 2010 to 2014 (84). This improvement was not only seen in patients undergoing autologous stem cell transplantation; patients treated with chemotherapy without autologous stem cell transplantation also demonstrated an improvement in 2-year survival from 25% to 47% during the same time periods.

TREATMENT. Treatment of all types of amyloidosis is directed at the underlying precursor protein. The mainstay of therapy is to stop production of the protein and to reduce the burden of amyloid infiltration. In addition, monoclonal antibody therapy designed to remove amyloid fibrils deposited in the heart and other tissues is being evaluated in clinical trials (87). Novel antibody therapy directed at the serum amyloid P component found in all forms of systemic amyloidosis with (R)-1-[6-[(R)-2-carboxy-pyrrolidin-1-yl]-6-oxo-hexanoyl]pyrrolidine-2-carboxylic acid (CPHPC), a drug that depletes circulating serum amyloid P, has been shown to clear hepatic amyloid deposits in a phase 1 study, but patients with cardiac involvement were excluded (88). Specific therapies for AL are directed at the plasma cell clone and consist of chemotherapy with or without autologous stem cell transplantation (70,89). Chemotherapeutic options include: bortezomib, melphalan combined with dexamethasone, daratumumab, and other agents, mostly derived from experience in treating multiple myeloma. A recent retrospective study found that the combination of bortezomib, dexamethasone, and an alkylating agent was associated with improved survival in patients with AL presenting with heart failure (89).

Diuretics are used for controlling congestive symptoms. However, low doses should be employed given the very noncompliant nature of the left ventricle. Conventional heart failure medications, including beta-blockers, angiotensin-converting enzyme inhibitors, or angiotensin receptor blockers, are poorly tolerated and should be avoided (68). Although sudden death is common, ICD therapy has not been shown to improve overall survival, as many patients die of pulseless electrical activity (70). Device implantation in AL is confounded by the increased risk of infection and bleeding in patients undergoing chemotherapy. Most experts do not recommend ICD implantation for primary prevention, although device therapy may be considered in selected patients, such as those awaiting cardiac transplantation (90). The indications for ICD use may expand with improvements in design and the option of a subcutaneous device.

Cardiac involvement is the most significant risk factor for autologous stem cell transplant, and patients with advanced heart failure are not candidates for this therapy (74,91). Highly selected patients with AL have undergone cardiac transplantation at centers with multidisciplinary teams experienced in treating amyloidosis resulting in a 50% 5-year survival rate (65,90). Selection for cardiac transplantation in AL is usually limited to those with minimal extracardiac involvement in whom there is reasonable expectation that the plasma cell clone can be controlled (68). Despite the overall improvement in survival, there is no cure for AL amyloid, and most surviving patients will require additional therapy. The central concept for cardiologists is to recognize that if AL can be diagnosed earlier, improved quality of life and survival are now possible.

TRANSTHYRETIN AMYLOIDOSIS

CLINICAL PRESENTATION. Hereditary ATTR. Transthyretin is a protein produced by the liver that transports thyroid hormone and retinol. In hereditary ATTR (ATTR-m), a pathogenic mutation leads to protein instability and misfolding. Patients with ATTR-m may demonstrate primarily neurological symptoms (peripheral and/or autonomic neuropathy), primarily cardiac involvement (heart failure, conduction system, arrhythmias), or a mixed phenotype (81,92). Vitreous opacities may occur as a small amount

of transthyretin is produced in the aqueous humor. Patients with ATTR-m may experience weight loss and gastrointestinal symptoms, particularly diarrhea and/or constipation. The gastrointestinal manifestations in some patients are primarily due to autonomic neuropathy rather than extensive gastrointestinal tract involvement, leading to delayed diagnosis, as gastrointestinal tract biopsies may be negative. Renal involvement may occur in ATTR-m, particularly those with the V30M mutation (93).

A positive family history is absent in one-half of patients with ATTR-m, which is endemic in parts of Sweden, Ireland, Portugal, Japan, and other countries. Although ATTR-m is generally considered to be very rare, the Val122Ile mutation is common in individuals of African or Caribbean descent and is found in 3% to 4% of blacks in the United States (94). It is important to consider ATTR-m in blacks with unexplained heart failure and increased myocardial thickness, including those with a history of hypertension. However, penetrance is incomplete with all of the known transthyretin mutations, and not all carriers will develop disease (95,96).

Wild-type ATTR. ATTR-wt (formally termed "senile systemic amyloidosis") is now known to be an important cause of arrhythmias and heart failure, especially in men >60 years of age (97). This age-related form of amyloid has been found in as many as 20% of patients undergoing transcatheter aortic valve replacement (98). Studies suggest that ATTR-wt is an important cause of HFpEF. One study demonstrated that 13% of patients with HFpEF and LV wall thickness >12 mm had ATTR-wt, with equal sex distribution (99). Previously thought to be exclusively a disease of elderly males, ATTR-wt is increasingly recognized in younger individuals, as early as the fifth decade (68). Although a striking male preponderance of 90% to 95% has been reported in the series to date, women are increasingly being diagnosed with this condition. Patients with ATTR-wt commonly present with heart failure, atrial arrhythmias, or conduction system disease. Carpal tunnel syndrome is present in approximately 40% at diagnosis, is usually bilateral, and generally precedes cardiac symptoms by 5 to 10 years (100). Although small systemic deposits of ATTR-wt occur throughout the body and can aid in establishing the diagnosis, the primary manifestations are usually cardiac. Bladder involvement is not uncommon and may lead to hematuria, particularly in patients taking anticoagulant therapy due to atrial fibrillation. The spinal ligaments may be involved leading to spinal stenosis. Spontaneous biceps tendon rupture is a clue to the diagnosis. Peripheral neuropathy may occur in ATTR-wt, but is less common than in ATTR-m.

DIAGNOSIS. The diagnostic strategy for both forms of ATTR is the same (**Figure 4**). The diagnosis may be established based on positive findings on fat aspirate, nerve biopsy, or another site, including the heart. It is important to recognize that a negative extracardiac biopsy does not exclude cardiac amyloidosis, and endomyocardial biopsy should be performed if strong clinical suspicion remains after initial screening tests. Low voltage on ECG is much less common in ATTR-wt (~25%) than in AL (~45%), despite markedly increased LV wall thickness in ATTR-wt (65). The reason for the discrepancy in ECG findings is not clear; however, this is a source of confusion as some cardiologists erroneously feel the diagnosis of amyloidosis is excluded if normal or increased ECG voltage is present. Compared with ATTR-m, ATTR-wt is characterized by greater LV wall thickness, greater depression of ejection fraction, and higher longitudinal strain. Patients with ATTR-wt have greater wall thickness but lower mortality (101). Both ATTR-m and -wt have findings similar to AL by echocardiography and CMR, including the "bullseye" pattern of strain. Although both types of ATTR demonstrate more dramatic myocardial thickening than in AL, this cannot be used to establish amyloid type. T_1 imaging has shown that extracellular volume is increased in AL compared with ATTR despite a lower mass, suggesting a component of true myocardial cell hypertrophy in ATTR and edema in AL (102,103). Although differences in T_1 findings have been reported in AL compared with ATTR, these are not sufficiently sensitive to accurately determine the type of amyloid. Patients with ATTR-wt more commonly demonstrate reduced LV ejection fraction compared with AL, which may occasionally be severe (81,104).

The biggest difference in clinical diagnosis of ATTR compared with AL is the ability to diagnose ATTR with nuclear scintigraphy if screening tests for a plasma cell disorder are negative (105). This represents a paradigm shift in the approach to diagnosis of amyloid, in which a tissue diagnosis was previously mandatory. For those who have typical clinical and imaging findings of amyloidosis and negative serum free light chains and serum and urine protein electrophoresis with immunofixation, grade 3 to 4 uptake of 99m-Tc pyrophosphate (PYP) is sufficient to establish the diagnosis (105). Further, subclinical cardiac involvement may also be detected with 99m-Tc PYP imaging when CMR and echocardiography remain nondiagnostic (106). Patients with AL and

apolipoprotein A1 amyloid may have mild uptake of 99m-Tc-PYP (usually not more than grade 1 to 2) (107). In addition, patients with ATTR (especially ATTR-wt) may commonly have MGUS, and thus, technetium pyrophosphate scanning alone is not sufficient in this subgroup and tissue typing for the type of amyloid may be required to make a diagnosis. However, in the absence of a monoclonal protein in serum or urine, a grade 2 to 3 positive PYP or other bone scintigraphy imaging study has a specificity and positive predictive value of almost 100% for cardiac ATTR amyloidosis (105), with the caveat that other rare forms of amyloid such as the apolipoprotein A1 type may result in positive scans and have not been adequately studied and can only be confirmed by tissue amyloid typing. All patients with ATTR should have transthyretin DNA sequencing performed to exclude ATTR-m.

PROGNOSIS. ATTR is generally much more slowly progressive than AL. Survival in ATTR-m depends in part on the specific mutation, some of which present much earlier in life than others (92). Although survival is measured in years rather than months in ATTR, life expectancy is reduced and quality of life is severely affected. The median overall survival in ATTR-wt described in multiple reports has been shown to be approximately 3.5 to 4 years (68,100,108).

TREATMENT. As with AL, the treatment strategy for ATTR is directed at the underlying protein disorder, with agents to reduce or eliminate the production of transthyretin, stabilize the protein, or disrupt deposited amyloid fibrils (109). Supportive therapy consists of diuretics for volume overload and control of atrial arrhythmias, which are particularly common in ATTR-wt. Conventional therapy for heart failure is often poorly tolerated in cardiac ATTR, similar to AL, although some patients may need a low-dose beta-blocker for rate control of atrial arrhythmias. The need for pacemaker implantation is not uncommon, especially in ATTR-wt (108). Conventional indications are generally used for pacing therapy. However, symptomatic bradycardia occurs in certain types of ATTR-m, and prophylactic pacemaker insertion is considered in those with a His-ventricular interval ≥70 ms, a His-ventricular interval >50 ms in the presence of fascicular block, or second-degree heart block (110).

Liver transplantation is a therapeutic strategy for ATTR-m and removes the predominant source of abnormal transthyretin (92). Liver transplant has been most commonly performed in younger individuals with the Val30Met mutation with primarily neurological involvement (111). Combined heart-liver transplantation is an option for those with severe cardiac involvement (92,112,113). Progression of amyloidosis after liver transplant alone could occur due to deposition of wild-type TTR on existing scaffolds of ATTR-m fibrils in the nerves, kidneys, or heart (114,115). In ATTR-wt, deposition in the myocardium continues in a time-dependent fashion despite liver transplantation. Curiously, the deposited protein is full-length TTR rather than the more typical TTR (116). Isolated heart transplantation may be considered for those with the V122I ATTR mutation, because presentation is often later in adulthood with limited extracardiac amyloid deposition (117). Post-liver transplant, it is reasonable to consider adjunct therapy with TTR stabilizers and/or anti-fibrillar agents to attempt to prevent progression of disease due to wild-type TTR deposition.

There is no proven pharmacological therapy specifically for ATTR with cardiac involvement, but a variety of emerging therapies are being tested in clinical trials and others are in development (118). The transthyretin stabilizer diflunisal has been proven to slow the progression of peripheral neuropathy in patients with ATTR-m (119). However, concerns about side effects such as fluid retention, renal insufficiency, and bleeding limit the use of diflunisal in those with advanced cardiac ATTR (65). Tafamidis is a transthyretin stabilizer that does not have the nonsteroidal anti-inflammatory properties of diflunisal; it has been proven to slow the progression of peripheral neuropathy in ATTR-m (120). The results of the phase 3 clinical trial of tafamidis in ATTR (-m and -wt) cardiac amyloidosis are expected in 2018 (121). Epigallocatechin-3-gallate, a component of green tea and curcumin, has transthyretin-stabilizing properties that may be beneficial in the treatment of ATTR.

Ribonucleic acid-interfering therapies (122,123) are being tested in clinical trials in ATTR-m patients with predominant neuropathy, including 2 phase 3 studies that are now reaching completion. However, a phase 3 study of ribonucleic acid-interfering therapy in cardiac patients was terminated early due to increased mortality in the treatment arm (65).

The combination of doxycycline and taurosodeoxycholic acid has been found to disrupt amyloid fibrils in a mouse model, although clinical data is limited (124,125). Doxycycline also appears to be a nonspecific inhibitor of amyloid formation and is sometimes used in AL, and along with other monoclonal antibodies directed against TTR (126-128), could be a promising emerging therapy for ATTR. Consideration needs to be given to referring patients with cardiac

JACC VOL. 71, NO. 10, 2018
MARCH 13, 2018:1130–48

amyloidosis to centers dedicated to treating the disease due to the complexity involved in diagnosing the various types of amyloid and the advanced often experimental treatment options available for patients.

ADDRESS FOR CORRESPONDENCE: Dr. G. William Dec, Cardiology Division, Massachusetts General Hospital, 55 Fruit Street, Yawkey 5B, Boston, Massachusetts 01224. E-mail: gdec@parnters.org.

REFERENCES

1. Richardson P, McKenna W, Bristow M, et al. Report of the 1995 World Health Organization/International Society and Federation of Cardiology Task Force on the Definition and Classification of Cardiomyopathies. Circulation 1996;93:841–2.

2. Elliott P, Andersson B, Arbustini E, et al. Classification of the cardiomyopathies: a position statement from the European Society Of Cardiology Working Group on Myocardial and Pericardial Diseases. Eur Heart J 2008;29:270–6.

3. Kushwaha SS, Fallon JT, Fuster V. Restrictive cardiomyopathy. N Engl J Med 1997;336:267–76.

4. Vaitkus PT, Kussmaul WG. Constrictive pericarditis versus restrictive cardiomyopathy: a reappraisal and update of diagnostic criteria. Am Heart J 1991;122:1431–41.

5. Garcia MJ. Constrictive pericarditis versus restrictive cardiomyopathy? J Am Coll Cardiol 2016;67:2061–76.

6. Gupta A, Singh Gulati G, Seth S, Sharma S. Cardiac MRI in restrictive cardiomyopathy. Clin Radiol 2012;67:95–105.

7. Rapezzi C, Arbustini E, Caforio AL, et al. Diagnostic work-up in cardiomyopathies: bridging the gap between clinical phenotypes and final diagnosis. A position statement from the ESC Working Group on Myocardial and Pericardial Diseases. Eur Heart J 2013;34:1448–58.

8. Cheng H, Zhao S, Jiang S, et al. The relative atrial volume ratio and late gadolinium enhancement provide additive information to differentiate constrictive pericarditis from restrictive cardiomyopathy. J Cardiovasc Magn Reson 2011;13:15.

9. Iles L, Pfluger H, Phrommintikul A, et al. Evaluation of diffuse myocardial fibrosis in heart failure with cardiac magnetic resonance contrast-enhanced T1 mapping. J Am Coll Cardiol 2008;52:1574–80.

10. Muehlberg F, Toepper A, Fritschi S, Prothmann M, Schulz-Menger J. Magnetic resonance imaging applications on infiltrative cardiomyopathies. J Thorac Imaging 2016;31:336–47.

11. Boynton SJ, Geske JB, Dispenzieri A, et al. LGE provides incremental prognostic information over serum biomarkers in AL cardiac amyloidosis. J Am Coll Cardiol Img 2016;9:680–6.

12. Geske JB, Anavekar NS, Nishimura RA, Oh JK, Gersh BJ. Differentiation of constriction and restriction: complex cardiovascular hemodynamics. J Am Coll Cardiol 2016;68:2329–47.

13. Cooper LT, Baughman KL, Feldman AM, et al. The role of endomyocardial biopsy in the management of cardiovascular disease: a scientific statement from the American Heart Association, the American College of Cardiology, and the European Society of Cardiology. Circulation 2007;116:2216–33.

14. Bennett MK, Gilotra NA, Harrington C, et al. Evaluation of the role of endomyocardial biopsy in 851 patients with unexplained heart failure from 2000-2009. Circ Heart Fail 2013;6:676–84.

15. Rajagopalan N, Garcia MJ, Rodriguez L, et al. Comparison of new Doppler echocardiographic methods to differentiate constrictive pericardial heart disease and restrictive cardiomyopathy. Am J Cardiol 2001;87:86–94.

16. Ling LH, Oh JK, Tei C, et al. Pericardial thickness measured with transesophageal echocardiography: feasibility and potential clinical usefulness. J Am Coll Cardiol 1997;29:1317–23.

17. Hurrell DG, Nishimura RA, Higano ST, et al. Value of dynamic respiratory changes in left and right ventricular pressures for the diagnosis of constrictive pericarditis. Circulation 1996;93:2007–13.

18. Hatle LK, Appleton CP, Popp RL. Differentiation of constrictive pericarditis and restrictive cardiomyopathy by Doppler echocardiography. Circulation 1989;79:357–70.

19. Oh JK, Hatle LK, Seward JB, et al. Diagnostic role of Doppler echocardiography in constrictive pericarditis. J Am Coll Cardiol 1994;23:154–62.

20. Welch TD, Ling LH, Espinosa RE, et al. Echocardiographic diagnosis of constrictive pericarditis: Mayo Clinic criteria. Circ Cardiovasc Imaging 2014;7:526–34.

21. Reuss CS, Wilansky SM, Lester SJ, et al. Using mitral 'annulus reversus' to diagnose constrictive pericarditis. Eur J Echocardiogr 2009;10:372–5.

22. Ha JW, Oh JK, Ling LH, Nishimura RA, Seward JB, Tajik AJ. Annulus paradoxus: transmitral flow velocity to mitral annular velocity ratio is inversely proportional to pulmonary capillary wedge pressure in patients with constrictive pericarditis. Circulation 2001;104:976–8.

23. Garcia MJ, Rodriguez L, Ares M, Griffin BP, Thomas JD, Klein AL. Differentiation of constrictive pericarditis from restrictive cardiomyopathy: assessment of left ventricular diastolic velocities in longitudinal axis by Doppler tissue imaging. J Am Coll Cardiol 1996;27:108–14.

24. Sengupta PP, Krishnamoorthy VK, Abhayaratna WP, et al. Disparate patterns of left ventricular mechanics differentiate constrictive pericarditis from restrictive cardiomyopathy. J Am Coll Cardiol Img 2008;1:29–38.

25. Masui T, Finck S, Higgins CB. Constrictive pericarditis and restrictive cardiomyopathy: evaluation with MR imaging. Radiology 1992;182:369–73.

26. Kojima S, Yamada N, Goto Y. Diagnosis of constrictive pericarditis by tagged cine magnetic resonance imaging. N Engl J Med 1999;341:373–4.

27. Bogabathina H, Biederman RW. Lack of slippage by cardiovascular magnetic resonance imaging is sine qua non for constrictive pericarditis. Circulation 2011;123:e418–9.

28. Kubo T, Gimeno JR, Bahl A, et al. Prevalence, clinical significance, and genetic basis of hypertrophic cardiomyopathy with restrictive phenotype. J Am Coll Cardiol 2007;49:2419–26.

29. Mogensen J, Arbustini E. Restrictive cardiomyopathy. Curr Opin Cardiol 2009;24:214–20.

30. Mogensen J, Kubo T, Duque M, et al. Idiopathic restrictive cardiomyopathy is part of the clinical expression of cardiac troponin I mutations. J Clin Invest 2003;111:209–16.

31. Kostareva A, Gudkova A, Sjoberg G, et al. Deletion in TNNI3 gene is associated with restrictive cardiomyopathy. Int J Cardiol 2009;131:410–2.

32. Kaski JP, Syrris P, Burch M, et al. Idiopathic restrictive cardiomyopathy in children is caused by mutations in cardiac sarcomere protein genes. Heart 2008;94:1478–84.

33. Wu W, Lu CX, Wang YN, et al. Novel phenotype-genotype correlations of restrictive cardiomyopathy with myosin-binding protein C (MYBPC3) gene mutations tested by next-generation sequencing. J Am Heart Assoc 2015;4:1–7.

34. Menon SC, Michels VV, Pellikka PA, et al. Cardiac troponin T mutation in familial cardiomyopathy with variable remodeling and restrictive physiology. Clin Genet 2008;74:445–54.

35. Sen-Chowdhry S, Syrris P, McKenna WJ. Genetics of restrictive cardiomyopathy. Heart Fail Clin 2010;6:179–86.

36. Purevjav E, Arimura T, Augustin S, et al. Molecular basis for clinical heterogeneity in inherited cardiomyopathies due to myopalladin mutations. Hum Mol Genet 2012;21:2039–53.

37. Brodehl A, Ferrier RA, Hamilton SJ, et al. Mutations in FLNC are associated with familial restrictive cardiomyopathy. Hum Mutat 2016;37:269–79.

38. Du J, Liu J, Feng HZ, et al. Impaired relaxation is the main manifestation in transgenic mice expressing a restrictive cardiomyopathy mutation, R193H, in cardiac TnI. Am J Physiol Heart Circ Physiol 2008;294:H2604–13.

39. Huby AC, Mendsaikhan U, Takagi K, et al. Disturbance in Z-disk mechanosensitive proteins induced by a persistent mutant myopalladin

causes familial restrictive cardiomyopathy. J Am Coll Cardiol 2014;64:2765–76.

40. Capetanaki Y, Papathanasiou S, Diokmetzidou A, Vatsellas G, Tsikitis M. Desmin related disease: a matter of cell survival failure. Curr Opin Cell Biol 2015;32:113–20.

41. Zhang J, Kumar A, Stalker HJ, et al. Clinical and molecular studies of a large family with desmin-associated restrictive cardiomyopathy. Clin Genet 2001;59:248–56.

42. Brodehl A, Gaertner-Rommel A, Klauke B, et al. The novel alphaB-crystallin (CRYAB) mutation p.D109G causes restrictive cardiomyopathy. Hum Mutat 2017;38:947–52.

43. Arbustini E, Pasotti M, Pilotto A, et al. Desmin accumulation restrictive cardiomyopathy and atrioventricular block associated with desmin gene defects. Eur J Heart Fail 2006;8:477–83.

44. Burke MA, Cook SA, Seidman JG, Seidman CE. Clinical and mechanistic insights Into the genetics of cardiomyopathy. J Am Coll Cardiol 2016;68:2871–86.

45. Arbustini E, Narula N, Tavazzi L, et al. The MOGE(S) classification of cardiomyopathy for clinicians. J Am Coll Cardiol 2014;64:304–18.

46. Yumoto F, Lu QW, Morimoto S, et al. Drastic Ca2+ sensitization of myofilament associated with a small structural change in troponin I in inherited restrictive cardiomyopathy. Biochem Biophys Res Commun 2005;338:1519–26.

47. Hayashi T, Shimomura H, Terasaki F, et al. Collagen subtypes and matrix metalloproteinase in idiopathic restrictive cardiomyopathy. Int J Cardiol 1998;64:109–16.

48. Angelini A, Calzolari V, Thiene G, et al. Morphologic spectrum of primary restrictive cardiomyopathy. Am J Cardiol 1997;80:1046–50.

49. Leya FS, Arab D, Joyal D, et al. The efficacy of brain natriuretic peptide levels in differentiating constrictive pericarditis from restrictive cardiomyopathy. J Am Coll Cardiol 2005;45:1900–2.

50. Reddy PR, Dieter RS, Das P, Steen LH, Lewis BE, Leya FS. Utility of BNP in differentiating constrictive pericarditis from restrictive cardiomyopathy in patients with renal insufficiency. J Card Fail 2007;13:668–71.

51. Ammash NM, Seward JB, Bailey KR, Edwards WD, Tajik AJ. Clinical profile and outcome of idiopathic restrictive cardiomyopathy. Circulation 2000;101:2490–6.

52. Bograd AJ, Mital S, Schwarzenberger JC, et al. Twenty-year experience with heart transplantation for infants and children with restrictive cardiomyopathy: 1986-2006. Am J Transplant 2008;8:201–7.

53. Topilsky Y, Pereira NL, Shah DK, et al. Left ventricular assist device therapy in patients with restrictive and hypertrophic cardiomyopathy. Circ Heart Fail 2011;4:266–75.

54. Seward JB, Casaclang-Verzosa G. Infiltrative cardiovascular diseases: cardiomyopathies that look alike. J Am Coll Cardiol 2010;55:1769–79.

55. Nagueh SF. Anderson-Fabry disease and other lysosomal storage disorders. Circulation 2014;130:1081–90.

56. Wu JC, Ho CY, Skali H, et al. Cardiovascular manifestations of Fabry disease: relationships between left ventricular hypertrophy, disease severity, and alpha-galactosidase A activity. Eur Heart J 2010;31:1088–97.

57. Linhart A, Kampmann C, Zamorano JL, et al. Cardiac manifestations of Anderson-Fabry disease: results from the international Fabry outcome survey. Eur Heart J 2007;28:1228–35.

58. Pieroni M, Chimenti C, Ricci R, Sale P, Russo MA, Frustaci A. Early detection of Fabry cardiomyopathy by tissue Doppler imaging. Circulation 2003;107:1978–84.

59. Luis SA, Maleszewski JJ, Young PM, Schaff HV, Pereira NL. Previously unreported in women *galactosidase alpha* pro409Ser variant is associated with Fabry disease. Circ Cardiovasc Genet 2017;10:e001661.

60. Weidemann F, Breunig F, Beer M, et al. Improvement of cardiac function during enzyme replacement therapy in patients with Fabry disease: a prospective strain rate imaging study. Circulation 2003;108:1299–301.

61. Mehta A, Beck M, Elliott P, et al. Enzyme replacement therapy with agalsidase alfa in patients with Fabry's disease: an analysis of registry data. Lancet 2009;374:1986–96.

62. Ortiz A, Abiose A, Bichet DG, et al. Time to treatment benefit for adult patients with Fabry disease receiving agalsidase beta: data from the Fabry Registry. J Med Genet 2016;53:495–502.

63. Maron BJ, Roberts WC, Arad M, et al. Clinical outcome and phenotypic expression in LAMP2 cardiomyopathy. JAMA 2009;301:1253–9.

64. Echaniz-Laguna A, Mohr M, Epailly E, et al. Novel Lamp-2 gene mutation and successful treatment with heart transplantation in a large family with Danon disease. Muscle Nerve 2006;33:393–7.

65. Maurer MS, Elliott P, Comenzo R, Semigran M, Rapezzi C. Addressing common questions encountered in the diagnosis and management of cardiac amyloidosis. Circulation 2017;135:1357–77.

66. Lousada I, Comenzo RL, Landau H, Guthrie S, Merlini G. Light chain amyloidosis: patient experience survey from the Amyloidosis Research Consortium. Adv Ther 2015;32:920–8.

67. Kyle RA, Linos A, Beard CM, et al. Incidence and natural history of primary systemic amyloidosis in Olmsted County, Minnesota, 1950 through 1989. Blood 1992;79:1817–22.

68. Grogan M, Scott CG, Kyle RA, et al. Natural history of wild-type transthyretin cardiac amyloidosis and risk stratification using a novel staging system. J Am Coll Cardiol 2016;68:1014–20.

69. Brenner DA, Jain M, Pimentel DR, et al. Human amyloidogenic light chains directly impair cardiomyocyte function through an increase in cellular oxidant stress. Circ Res 2004;94:1008–10.

70. Falk RH, Alexander KM, Liao R, Dorbala SAL. (light-chain) cardiac amyloidosis: a review of diagnosis and therapy. J Am Coll Cardiol 2016;68:1323–41.

71. Dubrey S, Pollak A, Skinner M, Falk RH. Atrial thrombi occurring during sinus rhythm in cardiac amyloidosis: evidence for atrial electromechanical dissociation. Br Heart J 1995;74:541–4.

72. Feng D. Intracardiac thrombosis and embolism in patients with cardiac amyloidosis. Circulation 2007;116:2420–6.

73. Milandri A, Longhi S, Gagliardi C, et al. Prevalence, risk factors and correlation with cardiac involvement of carpal tunnel syndrome in amyloidosis. Orphanet J Rare Dis 2015;10:P32.

74. Dispenzieri A, Buadi F, Kumar SK, et al. Treatment of immunoglobulin light chain amyloidosis: Mayo Stratification of Myeloma and Risk-Adapted Therapy (mSMART) Consensus Statement. Mayo Clinic Proc 2015;90:1054–81.

75. Gertz MA. Immunoglobulin light chain amyloidosis: 2011 update on diagnosis, risk-stratification, and management. Am J Hematol 2011;86:180–6.

76. Maleszewski JJ. Cardiac amyloidosis: pathology, nomenclature, and typing. Cardiovasc Pathol 2015;24:343–50.

77. Bellavia D. Detection of left ventricular systolic dysfunction in cardiac amyloidosis with strain rate echocardiography. J Am Soc Echocardiogr 2007;20:1194–202.

78. Maceira AM, Joshi J, Prasad SK, et al. Cardiovascular magnetic resonance in cardiac amyloidosis. Circulation 2005;111:186–93.

79. Ruberg FL. T1 mapping in cardiac amyloidosis: can we get there from here? J Am Coll Cardiol Img 2013;6:498–500.

80. Murtagh B. Electrocardiographic findings in primary systemic amyloidosis and biopsy-proven cardiac involvement. Am J Cardiol 2005;95:535–7.

81. Rapezzi C, Merlini G, Quarta CC, et al. Systemic cardiac amyloidoses: disease profiles and clinical courses of the 3 main types. Circulation 2009;120:1203–12.

82. Suresh R, Grogan M, Maleszewski JJ, et al. Advanced cardiac amyloidosis associated with normal interventricular septal thickness: an uncommon presentation of infiltrative cardiomyopathy. J Am Soc Echocardiogr 2014;27:440–7.

83. Maleszewski JJ. Relationship between monoclonal gammopathy and cardiac amyloid type. Cardiovasc Pathol 2013;22:189–94.

84. Muchtar E, Gertz MA, Kumar SK, et al. Improved outcomes for newly diagnosed AL amyloidosis between 2000 and 2014: cracking the glass ceiling of early death. Blood 2017;129:2111–9.

85. Kumar S, Dispenzieri A, Lacy MQ, et al. Revised prognostic staging system for light chain amyloidosis incorporating cardiac biomarkers and serum free light chain measurements. J Clin Oncol 2012;30:989–95.

86. Banypersad SM, Fontana M, Maestrini V, et al. T1 mapping and survival in systemic light-chain amyloidosis. Eur Heart J 2015;36:244–51.

87. Gertz MA, Landau H, Comenzo RL, et al. First-in-human Phase I/II study of NEOD001 in patients with light chain amyloidosis and persistent organ dysfunction. J Clin Oncol 2016;34:1097–103.

88. Richards DB, Cookson LM, Berges AC, et al. Therapeutic clearance of amyloid by antibodies to serum amyloid P component. N Engl J Med 2015;373:1106–14.

89. Sperry BW, Ikram A, Hachamovitch R, et al. Efficacy of chemotherapy for light-chain amyloidosis in patients presenting with symptomatic heart failure. J Am Coll Cardiol 2016;67:2941–8.

90. Davis MK, Kale P, Liedtke M, et al. Outcomes after heart transplantation for amyloid cardiomyopathy in the modern era. Am J Transplant 2015;15:650–8.

91. Comenzo RL, Gertz MA. Autologous stem cell transplantation for primary systemic amyloidosis. Blood 2002;99:4276–82.

92. Gertz MA, Benson MD, Dyck PJ, et al. Diagnosis, prognosis, and therapy of transthyretin amyloidosis. J Am Coll Cardiol 2015;66:2451–66.

93. Lobato L, Beirao I, Silva M, et al. End-stage renal disease and dialysis in hereditary amyloidosis TTR V30M: presentation, survival and prognostic factors. Amyloid 2004;11:27–37.

94. Jacobson DR, Pastore R, Pool S, et al. Revised transthyretin Ile 122 allele frequency in African-Americans. Hum Genet 1996;98:236–8.

95. Quarta CC, Buxbaum JN, Shah AM. The amyloidogenic V122I transthyretin variant in elderly black Americans. N Engl J Med 2015;372:21–9.

96. Buxbaum JN, Ruberg FL. Transthyretin V122I (pV142I)* cardiac amyloidosis: an age-dependent autosomal dominant cardiomyopathy too common to be overlooked as a cause of significant heart disease in elderly African Americans. Genet Med 2017;19:733–42.

97. Liu PP, Smyth D. Wild-type transthyretin amyloid cardiomyopathy: A missed cause of heart failure with preserved ejection fraction with evolving treatment implications. Circulation 2016;133:245–7.

98. Castaño A, Narotsky DL, Hamid N, et al. Unveiling transthyretin cardiac amyloidosis and its predictors among elderly patients with severe aortic stenosis undergoing transcatheter aortic valve replacement. Eur Heart J 2017;38:2879–87.

99. Gonzalez-Lopez E, Gallego-Delgado M, Guzzo-Merello G, et al. Wild-type transthyretin amyloidosis as a cause of heart failure with preserved ejection fraction. Eur Heart J 2015;36:2585–94.

100. Pinney JH, Whelan CJ, Petrie A, et al. Senile systemic amyloidosis: clinical features at presentation and outcome. J Am Heart Assoc 2013;2:e000098.

101. Quarta CC, Solomon SD, Uraizee I, et al. Left ventricular structure and function in transthyretin-related versus light-chain cardiac amyloidosis. Circulation 2014;129:1840.

102. Brooks J, Kramer CM, Salerno M. Markedly increased volume of distribution of gadolinium in cardiac amyloidosis demonstrated by T mapping. J Magn Reson Imaging 2013;38:1591–5.

103. Narotsky DL, Castano A, Weinsaft JW, Bokhari S, Maurer MS. Wild-type transthyretin cardiac amyloidosis: Novel insights from advanced imaging. Can J Cardiol 2016;32:1166.e1–10.

104. Grogan M, Dispenzieri A. Natural history and therapy of AL cardiac amyloidosis. Heart Fail Rev 2015;20:155–62.

105. Gillmore JD, Maurer MS, Falk RH, et al. Nonbiopsy diagnosis of cardiac transthyretin amyloidosis. Circulation 2016;133:2404–12.

106. Longhi S, Guidalotti PL, Quarta CC, et al. Identification of TTR-related subclinical amyloidosis with 99mTc-DPD scintigraphy. J Am Coll Cardiol Img 2014;7:531–2.

107. Castano A, Haq M, Narotsky DL, et al. Multicenter study of planar technetium 99m pyrophosphate cardiac imaging: Predicting survival for patients with ATTR cardiac amyloidosis. JAMA Cardiol 2016;1:880–9.

108. Connors LH, Sam F, Skinner M, et al. Heart failure resulting from age-related cardiac amyloid disease associated with wild-type transthyretin: a prospective, observational cohort study. Circulation 2016;133:282–90.

109. Dubrey S, Ackermann E, Gillmore J. The transthyretin amyloidoses: advances in therapy. Postgrad Med J 2015;91:439–48.

110. Algalarrondo V, Dinanian S, Juin C, et al. Prophylactic pacemaker implantation in familial amyloid polyneuropathy. Heart Rhythm 2012;9:1069–75.

111. Ericzon BG, Wilczek HE, Larsson M. Liver transplantation for hereditary transthyretin amyloidosis: after 20 years still the best therapeutic alternative? Transplantation 2015;99:1847–54.

112. Barreiros AP, Post F, Hoppe-Lotichius M, et al. Liver transplantation and combined liver-heart transplantation in patients with familial amyloid polyneuropathy: a single-center experience. Liver Transpl 2010;16:314–23.

113. Nelson LM, Penninga L, Sander K. Long-term outcome in patients treated with combined heart and liver transplantation for familial amyloidotic cardiomyopathy. Clin Transplant 2013;27:203–9.

114. Dixit N, Castano A, Farr MJ, et al. Rapidly progressive transthyretin-mediated amyloidosis in a Domino liver transplant recipient of a Ser23Asn donor. J Clin Neuromuscul Dis 2016;17:142–5.

115. Dubrey SW, Davidoff R, Skinner M, Bergethon P, Lewis D, Falk RH. Progression of ventricular wall thickening after liver transplantation for familial amyloidosis. Transplantation 1997;64:74–80.

116. Ihse E, Stangou AJ, Heaton ND, et al. Proportion between wild-type and mutant protein in truncated compared to full-length ATTR: an analysis on transplanted transthyretin T60A amyloidosis patients. Biochem Biophys Res Commun 2009;379:846–50.

117. Thenappan T, Fedson S, Rich J, et al. Isolated heart transplantation for familial transthyretin (TTR) V122I cardiac amyloidosis. Amyloid 2014;21:120–3.

118. Castano A, Drachman BM, Judge D, Maurer MS. Natural history and therapy of TTR-cardiac amyloidosis: emerging disease-modifying therapies from organ transplantation to stabilizer and silencer drugs. Heart Fail Rev 2015;20:163–78.

119. Berk JL. Repurposing diflunisal for familial amyloid polyneuropathy: a randomized clinical trial. JAMA 2013;310:2658–67.

120. Bulawa CE, Connelly S, DeVit M, et al. Tafamidis, a potent and selective transthyretin kinetic stabilizer that inhibits the amyloid cascade. Proc Natl Acad Sci U S A 2012;109:9629–34.

121. Coelho T, Maia LF, Martins da Silva A. Tafamidis for transthyretin familial amyloid polyneuropathy: a randomized, controlled trial. Neurology 2012;79:785–92.

122. Coelho T, Adams D, Silva A. Safety and efficacy of RNAi therapy for transthyretin amyloidosis. N Engl J Med 2013;369:819–29.

123. Ackermann EJ, Guo S, Booten S. Clinical development of an antisense therapy for the treatment of transthyretin-associated polyneuropathy. Amyloid 2012;19 Suppl 1:43–4.

124. Cardoso I, Saraiva MJ. Doxycycline disrupts transthyretin amyloid: evidence from studies in a FAP transgenic mice model. FASEB J 2006;20:234–9.

125. Obici L, Cortese A, Lozza A, et al. Doxycycline plus tauroursodeoxycholic acid for transthyretin amyloidosis: a phase II study. Amyloid 2012;19 Suppl 1:34–6.

126. Palladini G, Milani P, Merlini G. Novel strategies for the diagnosis and treatment of cardiac amyloidosis. Expert Rev Cardiovasc Ther 2015;13:1195–211.

127. Hosoi A, Su Y, Torikai M, et al. Novel antibody for the treatment of transthyretin amyloidosis. J Biol Chem 2016;291:25096–105.

128. Higaki JN, Chakrabartty A, Galant NJ, et al. Novel conformation-specific monoclonal antibodies against amyloidogenic forms of transthyretin. Amyloid 2016;23:86–97.

KEY WORDS amyloidosis, heart failure, restrictive cardiomyopathy